

BILATERAL VARIATIONS OF INFRACLAVICULAR PART OF BRACHIAL PLEXUS

A.K.Manicka vasuki, M.Jamuna, K.Kalyana sundaram, M.Nirmala devi



PSG Institute of medical sciences and research, Coimbatore.

ARTICLE INFO

Corresponding Author:

Dr. A. K. Manicka vasuki
PSG Institute of medical sciences and
research, Coimbatore.

Key words: Brachial plexus, Single
common cord, Median nerve,
Musculocutaneous nerve



DOI: <http://dx.doi.org/10.15520/ijmhs.2015.vol5.iss2.55>

ABSTRACT

Variations of the Brachial plexus and communication between its branches are commonly reported in literature. The present case describes bilateral variation of Brachial plexus in the infraclavicular part. During routine dissection of a male cadaver, a single common cord from which all branches of Brachial plexus were arising in the right upper limb. In the left upper limb, there was a communicating branch from Musculocutaneous nerve to Median nerve. These variations are important for Surgeons and Anaesthesiologists in their clinical practice during surgical and anaesthetic approaches in the region of axilla and arm.

©2015, IJMHS, All Right Reserved

INTRODUCTION

The ventral rami of C5,C6,C7,C8 and T1 spinal nerves take part in the formation of Brachial plexus.

The roots of Brachial plexus consists of C5,C6,C7,C8 and T1 ventral rami. They are located behind Scalenus anterior and medius muscles of neck.

Upper trunk is formed by the union of C5,C6 roots at the lateral margin of Scalenus medius muscle. Middle trunk is the continuation of C7 root. Lower trunk is formed by C8 and T1 roots behind the Scalenus anterior. As each trunk runs obliquely downwards towards middle one third of the clavicle, it terminates into anterior and posterior divisions just behind the clavicle.

The cords are **formed** at the cervicoaxillary canal. Lateral cord is formed by the union of anterior divisions of upper and middle trunks. Its root value is C5,C6 and C7. Branches from it are Lateral pectoral nerve, Lateral root of Median nerve and Musculocutaneous nerve.

Medial cord is formed by the continuation of anterior division of lower trunk. Its root value is C8,T1. Branches from it are Medial pectoral nerve, Medial root of Median nerve, Medial cutaneous nerve of arm, Medial cutaneous nerve of forearm and Ulnar nerve.

Posterior cord is formed by the union of all three posterior divisions. Its root value is C5,C6,C7,C8 and T1. Branches from it are Upper subscapular nerve, Lower subscapular nerve, Thoracodorsal nerve, Axillary nerve and Radial nerve.

MATERIALS AND METHODS

During routine dissection of a male cadaver, these variations were observed. Dissection was done on the right and left sides of the cadaver. The pectoral region, axilla and arm were dissected. The anatomical elements of the

Brachial plexus and its relation with Axillary artery and vein were observed.

CASE REPORT:

During routine dissection of a male cadaver, a rare bilateral variation of infraclavicular part of Brachial plexus was observed. The pectoral region, arm and axilla were dissected on both sides.

In the left upper limb, there was a communicating branch from Musculocutaneous nerve to Median nerve.

In the right upper limb, there was a single common cord from which all the branches of Brachial plexus were arising. The common cord was running posterolaterally to the axillary artery. The Musculocutaneous nerve, Medial cutaneous nerve of arm, Medial root of Median nerve were found medial to Axillary artery. Medial cutaneous nerve of forearm was absent. The other branches including Ulnar nerve, Lateral root of Median nerve, Radial nerve, Axillary nerve were found lateral to Axillary artery. All the branches were arising from a single common cord.

Instead of the lateral, medial and posterior cords of the Brachial plexus, only a single common cord was observed.

DISCUSSION

Variations in the pattern of the plexus can be due to abnormal formation in the development of the trunks, divisions or cords. The more common variations in the Brachial plexus are in the gross form at the level of junction or separation of its component parts.

Walsh [1] was the first, who described anatomical variations in the formation of Brachial plexus as a common trunk.

Singer [2] explained the single common cord of Brachial plexus is due to abnormal formation of Axillary

artery. The single common cord resulted from the connective tissue wrapping of the cords. Proper dissection of the connective tissue without interrupting nerve fibres resolved the plexus into normal one. In the present study, a single common cord was found in the right upper limb and a communicating branch from Musculocutaneous nerve to Median nerve was found in the left upper limb.

In a study by Jamuna.M[3], as a single common cord with absence of Musculocutaneous nerve was reported. This correlates with the present study which had a single cord but Musculocutaneous nerve was observed to be present.

Kerr [4] has studied the variations of Brachial plexus in man and classified the structure into three groups and seven subgroups. He reported the presence of two cords Anterior and posterior, where Medial and Lateral cords of classical Brachial plexus united to form Anterior cord which were lateral to Axillary artery. This does not correlate with the present findings.

Oluyemi [5] et al encountered only medial and lateral cords of Brachial plexus instead of three cords and three abnormal communications. An abnormal branch was arising from lateral cord which communicated with the medial cord before the origin of medial root of median nerve. A branch of posterior cord divided into Radial and Axillary nerves. This does not correlate with present finding.

Aggarwal, Puri et al [6] reported variation in the formation of Brachial plexus with two trunks and two cords and unusual relationship with Axillary artery. Two trunks were formed by union of primary rami of C5,C6,C7,C8 and T1 respectively which splitted and united in unusual manner to form two cords posterior and lateral. Medial cord was absent. This does not correlate with the present findings.

Shankar, Veeramani [7] reported a case of a common cord replacing medial and lateral cords. In his report common cord was observed lateral to second part of Axillary artery which was similar to the present case.

Agarwal, Harjeet et al [8] reported the presence of two trunks which form two cords : Posterior and lateral instead of three. Medial cord was absent. Both cords were found superolateral to 2nd part of Axillary artery And Median nerve was formed from a single cord.

Jamuna,Amudha [9] reported Brachial plexus with two cords Anterior and posterior which were lateral to Axillary artery. This does not correlate with the present findings.

Pavan P Havaladar, Anjali Gupta et al [10] reported two trunks. Middle trunk was absent. C5 and C6 joined to form upper trunk. C7,C8 and T1 joined to form lower trunk. Anterior divisions of upper and lower trunks join to form superior cord and posterior divisions of the two trunks join to form Inferior cord. Both the cords were lateral to Axillary artery. This does not correlate the present finding.

CONCLUSION:

Knowledge of Brachial plexus variation has important anatomical, surgical and clinical applications especially in relation to Trauma and Surgical procedures of upper limb. The present case provides additional knowledge on Brachial plexus variationsto clinicians which may help to avoid damage during surgical proceduresrelated to Plastic and reconstructive surgery. It is also important to be aware of these variations during Brachial plexus block and in nerve entrapment syndromes involving different branches of Brachial plexus.

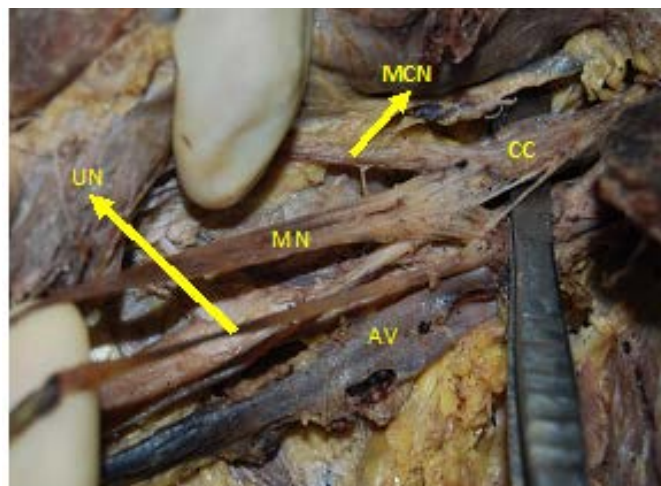


Figure 1: Shows Common single cord with its branches. CC - Common single cord, MCN - Musculocutaneous nerve, MN - Median nerve with medial and lateral roots, UN - Ulnar nerve, AV - Axillary vein

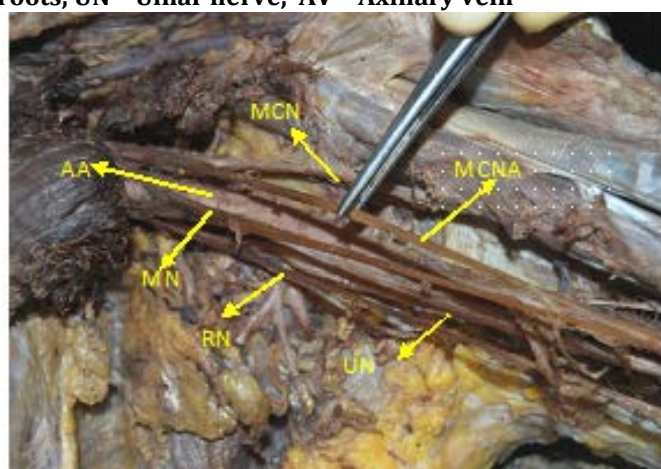


Figure 2: Shows MCNA - Medial cutaneous nerve of of arm, MCN - Musculocutaneous nerve with Medial root of Median nerve were found medial to Axillary artery and UN- Ulnar nerve, RN - Radial nerve, Lateral root of Median nerve were found lateral to Axillary artery, AA - Axillary artery, MCNA - Medial cutaneous nerve of arm

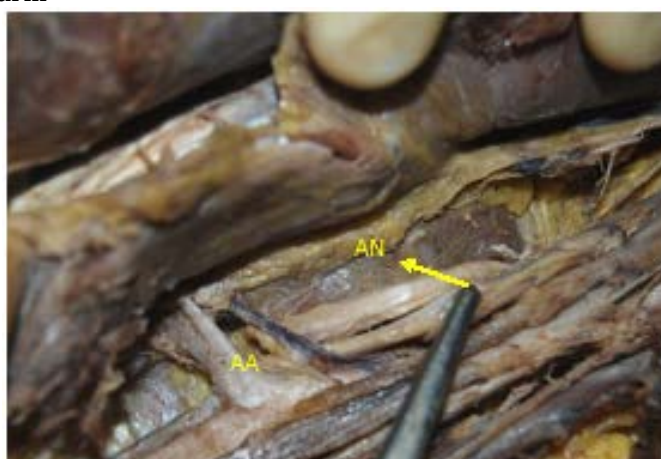

Figure 3: Shows AN - Axillary nerve was found lateral to the Axillary Artery (AA). Radial nerve was deeper to Axillary nerve. Ulnar nerve was medial to Axillary nerve.

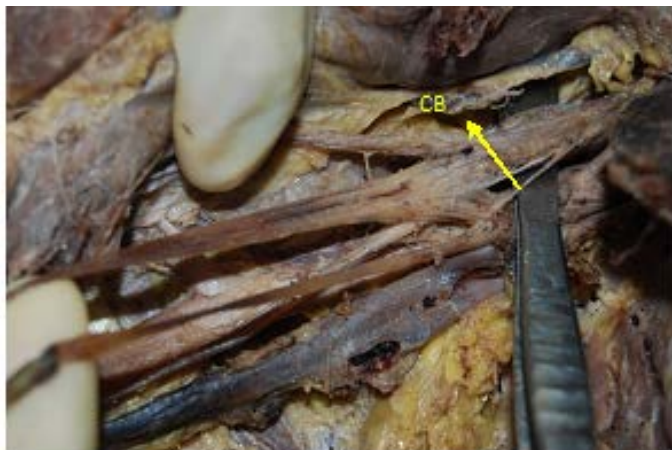

Figure 4: Shows a communicating branch to Median nerve from Musculocutaneous nerve in the left upper limb

REFERENCES:

1. Walsh.J.F. the anatomy of the brachial plexus. Am.J.Med.Sci. 1877; 74: 388 -99
2. Singer E. Human brachial plexus united into a single cord. Description and interpretation.Anat.Rec 1933: 55:411 -19
3. Jamuna.M. A single common cord in the infraclavicular part of brachial plexus. IJHSR – ISSN 2249 – 9571 : 2012
4. Kerr AT. The brachial plexus of nerves in man, the variations in its formation and its branches.A.M.J.Anat 1918:23: 285 – 395
5. Oluyemi KA,Adesanya OA, ofusori DA etal: Abnormal pattern of brachial plexus formation: An original case report. The internet J.Neurosurg 2007;4: Number2
6. Aggarwal A, Puri N, Aggarwal AK et al Anatomical variation in the formation of brachial plexus and its branching. Surgical and radiological anatomy 2012;32(9): 891 – 94
7. Shankar N, Veeramani R Replacement of the medial and lateral cords of brachial plexus by a common cord and its trifurcation into major brachial. International J.Anatomical variations.2010;3:205 – 07
8. Agarwal A, Harjeet K, Sahini D,et al Bilateral multiple complex variations in the formation and branching pattern of brachial plexus. Surg.Radio.Anat.2009; 31(O) : 723 – 31.Epub 2009 Apr 22
9. Jamuna M, Amudha G.Two cord stage in the infraclavicular part of brachial plexus.International J.Anatomical variations2010; 3: 128 – 29
- 10.Pavan P.Havaladar, Anjali Gupta et al. Variation in the formation of cords of Brachial plexus its relation with Axillary artery. Current Neurobiology 2012; 3(1): 7 - 9

How to cite this article: Kandavadivelu, Manickavasuki. Bilateral Variations of Infraclavicular part of brachial plexus. *Innovative Journal of Medical and Health Science*, [S.l.], v. 5, n. 2, p. 70-72, apr. 2015. ISSN 2277-4939. Available at: <<http://innovativejournal.in/ijmhs/index.php/ijmhs/article/view/55>>. Date accessed: 27 Apr. 2015. doi:10.15520/iimhs.2015.vol5.iss2.55.