

## CONTACT LENSES WEARING. HOW MUCH DO PATIENTS KNOW AND HOW TO IMPROVE IT.

Mohammed Talouzi, Walid Sharif, Ibrahim Elaraoud



Birmingham and Midlands Eye Centre

### ARTICLE INFO

#### Corresponding Author:

Ibrahim Elaraoud  
Birmingham and Midlands Eye  
Centre  
I\_melaroud@hotmail.com

**Key words:** Women's autonomy,  
maternal health, decision making.



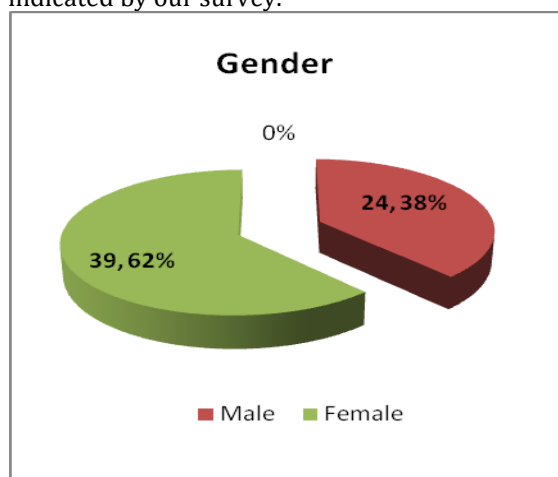
DOI: <http://dx.doi.org/10.15520/ijmhs.2016.vol6.iss6.144>.

### ABSTRACT

**Aim:** To assess the level of knowledge and experience of contact lens users who have attended the eye casualty seeking advice and treatment for contact lens related problem. The article will also provide a concise review of the literature regarding contact lens history, types, uses and complications and explore the pathophysiology of the contact lens related conditions. The article will discuss the management and preventive measures for those conditions that may lead to blindness. **Methods:** Prospective review of patients who have attended a regional eye casualty over a period of January to March 2015. Patients were recruited following the triage details provided. The inclusion criteria was all contact lens users aged 16 years and above and have been using contact lens for a minimum of 6 months. Survey questionnaire were given to patients who filled them prior to their consultation with the ophthalmologist. The audit was registered with the clinical effectiveness department of the author's Trust. Extensive review of the literature in regards to contact lens also has been carried out. **Results:** There were a total of 63 patients under review during the study period consisting of 29 males and 34 females. Ages ranged from 16–80 years. The most common type of lenses used is the soft monthly contact lenses which were found in 55.5% of the target group. The survey has shown the optician as the main provider for the lens in 95%, with the remaining of patients order them online. More than 60% of the target group have shown bad behaviour in sleeping, swimming and showering while having the contact lens in. The majority have indicated that they were given instructions on insertion and removing of the contact lens. However 33.4% have not had information when to seek medical advice. The main source of information given to the users was the optician in 58.8% followed by other resource such as internet, leaflets, and friends in 39.6%. Neither the GP nor the nurse has shown to provide any advice and this could be explained as the optician is the main contact and provider for the contact lens and the only contact with the GP or the Practice nurse would be when there is an issue with the ocular health. The daily duration of wearing contact lens ranged from 4-18 hrs. The figures given has shown an over usage of such lens by some of those users. Furthermore, 55.5% of the users have indicated the using of lubrication eye drops with their contact lens. 1 in 2 have experienced contact lens related issues prior to their attendance that range from dry eyes to sight threatening corneal ulcers. Finally 57% of the target group have been diagnosed with contact lens related infective keratitis and have been treated with intensive topical antibiotics, while the rest have other contact lens related issue that varies from tear film disturbance to allergic conjunctivitis and superficial punctate keratitis. The survey strongly emphasises the need to re-educate contact lens users about the standard guidelines and activities required to follow while wearing contact lenses. **Conclusion:** Providing advice and education to the contact lenses users is imperative and following the standard guidelines of contact lens care is essential for users in order to avoid any sight threatening condition. There is a need to re-educate patients regarding their contact lens care and the preventive measure of contact lens related complications.

## INTRODUCTION

Contact lenses are the smallest, least visible and the finest devices used for correcting refractive errors by placing them directly on the surface of the eye. Contact lenses are considered medical devices and can be worn for therapeutic reasons. Additionally, Contact lens can be used for cosmetic purposes (Farandos et al 2014). Prescribing and fitting contact lenses have become an integral part of today's comprehensive ophthalmology practice (Lemp & Bielory 2008). Millions of people across the world are wearing contact lenses and 1.65 million people across the UK use contact lens (Dart et al 2009). Contact lenses are used in either sex at different age groups as indicated by our survey.



Age group	Number of patients
16-29	20
30-44	24
45-60	13
Over 60	6

## History

It is important to inquire into the origins and stages of development for contact lenses. The idea of the contact lens was introduced by Leonardo da Vinci in 1508 by which he described a method to alter the corneal power through wearing a water-filled glass hemisphere over the eye (Heitz, and Enoch 1987).

In 1636 René Descartes invented a glass tube filled with liquid. This was placed directly to the cornea where the protruding end composed of clear glass shaped to correct vision. Unfortunately this was impracticable as this would make blinking impossible.

In 1801 Thomas Young, attempted to neutralize refractive power and made a basic pair of contact lenses based on Descartes model. Adolf Gaston Eugen Fick was the first to construct and fit the first successful contact lens in 1888. It was described as fabricating focal scleral contact shells which rest on the less sensitive rim of tissue around the cornea (Agrawal 1972). Until the 1930s the glass-blown scleral lenses remained the only form of contact lens and the development of the polymethyl methacrylate (PMMA or Perspex/Plexiglas), allowing plastic scleral lenses to be manufactured for the first time ([www.sciencemuseum.org.uk](http://www.sciencemuseum.org.uk)).

In 1936, optometrist William Feinbloom introduced the lighter and the most convenient plastic lens which was a combination of glass and plastic. The first "corneal" lenses were developed in 1946 (Robert and Mandel 1988) and was described as smaller than the original scleral lenses

and they sat only on the cornea rather than across the visible ocular surface. Those lenses could be worn up to sixteen hours per day. PMMA corneal lenses became the first contact lenses to have mass appeal through. In 1960, Wichterle discovered the soft contact lens which is made up of hydrophilic material (Pearce, Jeremy 2007)

The first silicone hydro-gel lens was launched into the market in 1998 by Ciba Vision in Mexico. Those lenses have encapsulated the benefits of silicone of extremely high oxygen permeability with high degree of comfort and clinical performance compared to the conventional hydrogels that had been used for the previous 30 years. Such lenses were initially advocated primarily for extended wear (day and night), although more recently, daily (not overnight) wear silicone hydrogels have been launched (Pearce, Jeremy 2007).

## Types

Modern system classifies contact lens into three major types such as

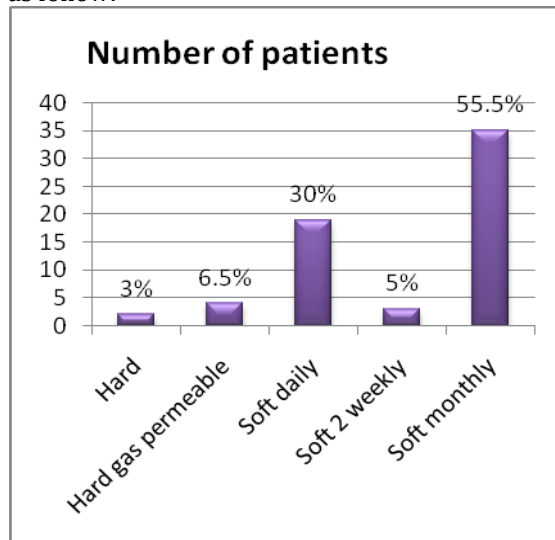
1. Hard contact lens  
These are glass lenses and are the first lens made from polymethyl methacrylate (PMMA or Perspex/Plexiglas). The rigid lenses have been around for about 120 years and the main disadvantage is not allowing enough oxygen to pass through to the cornea, which can cause a number of adverse clinical events (Stollery et al 2005)
2. Rigid gas permeable (RGP)  
These lenses are made of complex polymers this may include silicone, PMMA and others. Those lenses permit excellent perfusion of oxygen (Denniston & Murray 2006)
3. Soft contact lenses  
Soft lenses are developed recently by Otto Wichterle who has launched the first soft (hydrogel) lenses in some countries in the 1960s and the approval of the "Soft lens" daily material (polymacon) by the United States FDA in 1971. Soft lenses are usually comfortable shortly after insertion, while rigid lenses require a period of adaptation before full comfort is achieved. The biggest improvements to soft lens polymers have been increasing oxygen permeability, lens wettability, and overall comfort (Albert et al 2008).

In 1998, silicone hydrogels became available. Silicone hydrogels have both the extremely high oxygen permeability of silicone and the comfort and clinical performance of the conventional hydrogels. As silicone allows more oxygen permeability than water, the oxygen permeability of silicone hydrogels is not tied to the water content of the lens. Lenses have now been developed with so much oxygen permeability that they are approved for overnight wear (extended wear). Lenses approved for daily wear are also available in silicone hydrogel materials ([www.eyecandys.com](http://www.eyecandys.com)).

The disadvantages of silicone hydrogels are that they are slightly stiffer and the lens surface can be hydrophobic, and thus, less "wetable." These factors can influence the comfort of the lens. New manufacturing techniques and changes to multipurpose solutions have minimized these effects. A surface modification process called plasma coating alters the hydrophobic nature of the lens surface. Another technique incorporates internal rewetting agents to make the lens surface hydrophilic. A third process uses longer backbone polymer chains that results in less cross linking and increased wetting without surface alterations

## Ibrahim/Contact lenses wearing. How much do patients know and how to improve it.

or additive agents (Hancu et al 2011, Albert et al 2008). Our survey indicates the users of the contact lens per type as follow:



Types of Contact lens	Number of patients
Hard	2
Hard gas permeable	4
Soft daily	19
Soft 2 weekly	3
Soft monthly	35

### Functions

#### 1. Corrective contact lenses.

Corrective contact lenses are designed to improve vision, most commonly by correcting refractive error. This is done by directly focusing the light so that it enters the eye with the proper power for clear vision (Behjamine 2009)

#### 2. Cosmetic contact lenses.

A cosmetic contact lens is designed to change the appearance of the eye (worn to change the colour of the eye). These lenses may also correct refractive error. Furthermore, painted contact lenses are worn by albinos or people with aniridia (Absence of iris) to prevent too much light entering the eye (Strollery et al 2005).

#### 3. Therapeutic lenses.

**Therapeutic Scleral lens** is a large, firm, oxygen permeable lens that rests on the sclera and creates a tear-filled vault over the cornea. Those lenses are used in patients with sensitive cornea in order to help support it directly.

- Scleral lenses may be used to improve vision and reduce pain and light sensitivity for people suffering from growing number of disorders or injuries to the eye, such as severe dry eye syndrome (Keratanconjunctivissicca).
- Scleral lenses are used in keratoconus and for eyes that have undergone a cornea transplant, and for people with severe dry eyes caused by conditions such as Sjogren's syndrome and Stevens-Johnson syndrome.
- Scleral lens are used in microphthalmia, corneal ectasia, neurotrophic keratitis (anaesthetic corneas). (Hancu et al 2011, Albert et al 2008, Romero-Jimene et al 2010, Kanski 2009).

#### b) Therapeutic soft lenses.

**Soft lenses** are often used in the treatment and management of non-refractive disorders of the eye (Hancu et al 2011). These lenses will be used in the following highlighted conditions.

- Mechanical corneal protection - in conditions such as entropion, trichiasis, tarsal scars, recurrent corneal erosion and post-surgical ptosis for corneal protection.
- To increase comfort and corneal pain relief - in conditions such as bullous keratopathy, epithelial erosion and abrasion, filamentary keratitis, post-keratoplasty.
- For use as a bandage during the healing process to improve corneal re-epithelization in many conditions such as chronic epithelial defects, corneal ulcer, neurotrophic keratitis, neuroparalytic keratitis, chemical burns, and post-surgical epithelial defects.
- Wound healing for post-surgical conditions such as LASIK, PRK, PK, PTK, lamellar grafts, corneal flaps, and additional corneal surgical conditions.
- Vision enhancement. Use of plano or powered contact lenses to smooth an irregular corneal surface; counteract under or over-correction after refractive surgery, and maintain ocular surface hydration.
- Prevents tear evaporation or provides a moisture reservoir for the ocular surface in cases of severe dry eye
- Tectonic effect in descematocele after corneal laceration also in corneal or cornea scleral laceration without endoocular membrane issue. (Ambroziak et al 2004, Szaflik et al 2004, Albert et al 20008, Kanski & Bowling 2011, Hancu et al 2011)

### Contact lens complication

#### a) Problems with the lens itself

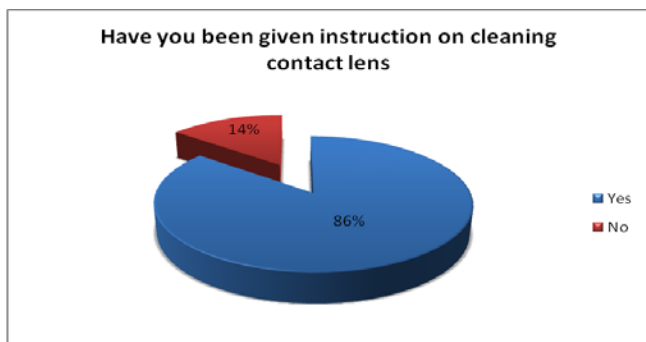
##### 1) Poor lens fit.

This is either tight or loose lens fitting that can cause damage. Tight lenses typically feel comfortable initially and then become increasingly uncomfortable over a period of hours. With continued use, tight lens syndrome can develop corneal erosion, irritation and soreness. Tight lens syndrome is due to non-moving contact lens on blinking and appears sucked on to the cornea (Albert et al 2008). This condition also occurs after re-wearing soft contact lens that has dried out then rehydrated (Rhee & pyfer 2002). An imprint in the conjunctiva is often observed after the lens is removed. Corneal oedema usually anterior and superficial punctate keratitis is observed. In this case, the contact lenses need to be removed and the use of cycloplegia in severe inflammation cases and preservative free artificial tears is recommended (Tsai et al 2011).

##### Contact lens deposits and poor care.

Caring of the contact lens is vital and failure to clean the lenses properly may lead to the accumulation of multiple small deposits of protein and lipid on the contact lens. These can cause irritation of the cornea and impaired visual acuity. Additionally, bacteria protozoa and fungi can form a film over the lens and the fungal filaments would invade the lens itself (Szcotka et al 2010). The contact lens is often old and may not have been cleaned or enzyme treated properly (Rhee & pyfer 2002). Deposits on the contact lens also damage the lens surface and increase the risk of further eye damage. There is also a need to avoid the lenses from any contact with hairspray, make-up, smoke and hand cream. It is important to ensure that the patient is using the lenses correctly so as to prevent future deposit formation (Szcotka et al 2010)

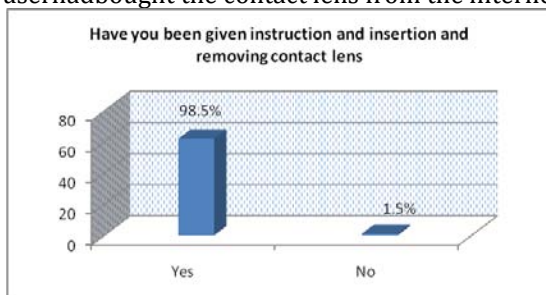
Our survey revealed that 86% of the target group have been given instructions on how to clean their contact lens. This is a vital and important issue in care and handling the contact lens and the need to always keep users of contact lens on the track for the care of the contact lens.



### 3) Lens damage.

Damage of the Contact Lens is more common with soft lenses than with rigid gas-permeable (RGP) lenses. Damage of the contact lens comes in the form of tears, cracks and chips. These may cause local irritation of the cornea. The lens is then also at greater risk of pathogen colonisation, giving rise to conjunctivitis or keratitis. This could happen with the wrong technique of insertion and removing the contact lens (Albert et al 2008)

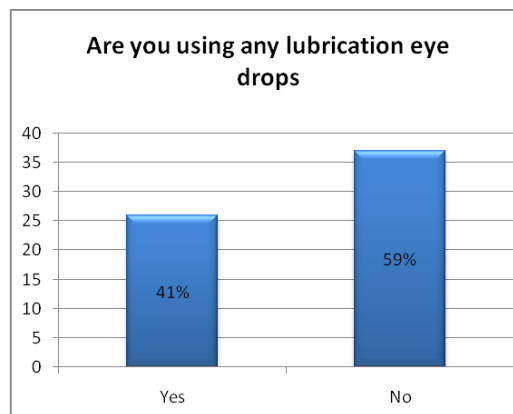
It is usually the responsibility of the providers of the contact lens to teach the users how to insert and remove the contact lens. This would usually happen at the practice of the optician or at the hospital. The survey questionnaire has shown that 98.5% of the users have been taught how to insert and remove the contact lenses and only 1.5% has not been taught about this. Investigation showed that this user had bought the contact lens from the internet.



### c) Lens drying.

The contact of the current soft lens polymers varies approximately from 38% to 75% which is the property that determine the oxygen permeability. Lens drying is of the complication that may occur in soft contact lens. This would be due to appearance of 'staring' or reduced blink rate. The users will start to have discomfort and foreign body sensation which may also indicate corneal hypoxia (Albert et al 2008)

The survey questionnaire has explored the time duration for the daily contact lens use which range from 6-18 hrs. Furthermore, more than half indicated the use of more than 10 hours daily. The target group was asked if they have been using any lubrication eye drops and the majority have indicated that they never used any eye drops before their visit to the eye hospital where the longer usage of contact lens leads to dryness of the eye and the contact lens.



### Conjunctival Problem

1. Allergic conjunctivitis. This arises due to sensitivity to thiomersal, a preservative used in Contact Lens care solutions. This condition presents with redness, burning and itching which is worse on lens insertion and reduces over time. But diagnosis is tricky and the conjunctivitis may only gradually appear days or months after initial exposure. There will be evidence of peri-limbal injection (redness just around the cornea) and papillary reaction (Benjamin L 2009). Treatment is to avoid the thiomersal and advise patients to visit their CL provider for alternative lens care solutions (Tsai et al 2011).

#### 2. Giant papillary conjunctivitis

This allergic condition arises as a direct consequence of the lens itself. This occurs from the mechanical trauma with the lens on the upper tarsal conjunctiva amplifying a hypersensitivity response to the allergens on the lens surface (Benjamin 2009). This would present as intolerance to the lens associated with irritation and redness of the eye, itchy and mucous discharge in the presence of giant papillae (>3.0 mm) in the upper tarsal conjunctiva (Krachmer et al 2011). These are thought to be due to chronic irritation and mediated by both immune and mechanical means. The treatment consists of removing the lens until the condition has resolved, and improving care/fit of lenses. Topical mast cell stabilisers (such as Sodium Cromoglicate) may be used; preservative free drops should be instilled. (Denniston & Murray 2006)

#### 3. Toxic conjunctivitis.

This could happen as a result of the cleaning solutions used for the lens due to absorption into the lens of the preservatives. Disinfectant/enzyme is inadvertently introduced into the eye. This could be substances which may be on the hand of the wearer when inserting the lens such as perfume or hand cream. Conjunctival injection and ocular irritation typically develop shortly after lens cleaning and insertion but can be present chronically. Also a recent change from one type or brand of solution to another is often elicited in this history (Ehlers et al 2011). Eye examination reveals diffuse punctate epithelial erosion ± subepithelial infiltrates and keratoconjunctivitis. The main treatment is to remove the lens and preservative free artificial tears until the condition has resolved (Denniston and Murray 2006). It is recommended to leave enough and adequate time of rinsing lens after the enzyme use (Rhee & Pyfer 2002).

### c) Corneal problems

#### 1. Superficial punctate keratitis (SPK).


This would happen as hypersensitivity to the bacterial exotoxins. This is the most common problem associated with CL wear and may occur as a result of dry eye and over use of the contact lens. This ranges from epithelial



thickening to pseudodendritics changes (Benjamin 2009). It usually presents as red, sore and watery eyes with foreign body sensation. Clinical signs characterised as punctate epithelial erosion ± subepithelial infiltrates which is mainly in the peripheral of the cornea and keratoconjunctivitis. Superficial punctate keratitis (SPK) (Rhee & Pyfer 2002). This is non-infectious in origin but could arise in one of the following conditions described below. Infectious infiltrates are typically more central than sterile infiltrates larger with a definite epithelial defect and have anterior chamber reaction (Benjamin 2009, Yanoff & Ducker 2004)

- a) Mechanical injury. This would happen due to cracked or damaged lenses or trauma while inserting or removing the contact lens. This would result from the friction of accumulated debris on the lens (Benjamin 2009)
  - b) Tight lens syndrome. This is seen with the hard lens or if the lenses are worn overnight. The lens does not move on blinking and appears to be stuck on the cornea. There is generalised corneal epithelial oedema with punctate epithelial erosions and neovascularisation (Alert et al 2008). This will be aggravated by decreased blink rate and low-rising rigid CLs, resulting in inadequate lid closure and poor condition of the patient's lids/meibomian glands/tear. The main treatment is to remove the lens; use preservative free artificial tears; substitute the cleaning solution to another one and educate patients about contact lens care (Tsai et al 2011).
  - c) Corneal hypoxia. Corneal hypoxia occurs due to decreased oxygen diffusion produced by the lens and the tear film. This is because the tear exchange under the soft lenses is limited approximately 1% and the corneal epithelium is solely dependent on the oxygen diffusing through the lens (Albert et al 2000). This would occur when individuals do not replace lenses or use them beyond the recommended time. There are two stages that would happen in hypoxic cornea. The acute stage, where pain and soreness that results in corneal ulceration and corneal oedema (Krachmer et al 2011). However the chronic stage which is asymptomatic results in changes to the corneal structure with neovascularisation (Rhee & Pyfer 2002). Treatment is by removal of the lens and treating the corneal ulcer with topical antibiotics and cycloplegic agents. Patients should be fitted with RGP lenses if they wish to continue wearing CLs and should be educated with regard to the healthy use of the contact lens (Kanski & Bowling 2011)
  - d) Toxic Keratopathy would happen when a disinfectant/enzyme in advertently is introduced into the eye that results in diffuse punctate epithelial erosion ± subepithelial infiltrates. The main treatment is to remove the lens until the condition has resolved and use preservative free artificial tears and re-educate patients regarding the contact lens care (Tsai et al 2011)
2. Tear film disturbance. Poor blink response or ill fitting lens results in punctate staining on the cornea with interpalpebral hyperaemia. Treatment is by removing the contact lens and using preservative free artificial tears. Also checking the contact lens fit. (Denniston and Murray 2006)
  3. Microbial keratitis  
Microbial Keratitis (also referred to Corneal Ulcer) is one of the major complications of contact lens (CL) (Wani 2010). Microbial keratitis with its complications is not restricted to any particular country. Contact lens is favoured and worn by many people all over the world. Contact lens

related keratitis could be a sight threatening issue which require rapid diagnosis and treatment to prevent vision loss (Tananuvat et al 2008). The collected data from the survey have shown that 57% of patients attended the eye casualty seeking treatment were diagnosed with contact lens related infective keratitis and have been treated with intensive topical antibiotics. The graph below illustrates the contact lens related complications revealed by the survey data collected on the day of examination.




Microbial keratitis occurs when there is a loss of the corneal epithelium, with underlying stromal infiltration, and suppuration associated with signs of inflammation with or without hypopyon. This will lead to interruption to the continuity of intact corneal epithelium and/or abnormal tear film which will permit entrance of microorganisms into the corneal stroma and appear to demonstrate attachment to the edge of epithelial wound. Once the attachment has occurred, the destruction process of inflammation, necrosis and angiogenesis can ensure. Certain bacteria produce toxins that inhibit protein synthesis and proteases such as alkaline proteases and elastases that stimulate necrosis (the premature death of cells and living tissue) (Norina et al 2008).

The most common groups of bacteria responsible for bacterial keratitis are as follows: streptococcus, Pseudomonas, Enterobacteriaceae (including Klebsiella, Enterobacter, Serratia, and Proteus), and Staphylococcus species. However, pseudomonas aeruginosa is the most dangerous bacteria that can lead to large destruction of the cornea (Lim et al 2008). Pseudomonas ulcers produce copious greenish yellow discharge and rapidly progresses to hypopyon formation and corneal perforation. The surrounding cornea may have ground glass appearance (Wani 2011). Acanthamoeba spp. can cause a rare but potentially devastating sight-threatening keratitis. This type of keratitis is suspected in the patient who gave a history of swimming. Acanthamoeba thrives in soil and water environments such as swimming pools, ponds, hot tubs and contact lens saline solution (Yanoof and Duker 2004). Patient will usually present with red, foreign body sensation, watering, irritation and discomfort, mucopurulent discharge from eye, pain, photophobia and blurred vision. They may also notice focal white opacity in the corneal stroma (Norina et al 2008, Kanski 2009, Yanoof and Ducker 2004)

It is important for the contact lens users to seek medical advice once the above symptoms appear. This will require comprehensive eye examination and management. Additionally, contact lens and cleaning solution might need to be cultured. A corneal scrape may also need to be cultured to find out the type of organism. Intensive topical antibiotics ± hospital admission will be required. Regular

follow ups will need to be arranged (Rhee and Pyfer 2002).The survey revealed that 1 in 2 experienced some contact lens related complication prior to their attendance to the eye casualty.



### Care of contact lens

Contact lenses require great care to prevent any damage to the cornea and avoid any eye sight threatening complication. Regardless of the brand of the contact lens, there are a few principles which need to be applied in the care of the contact lens. Our survey has questioned the target group on activities that should be avoided in the care of contact lens. Such activities might have negative impact on eyes. Those are reported as follows:

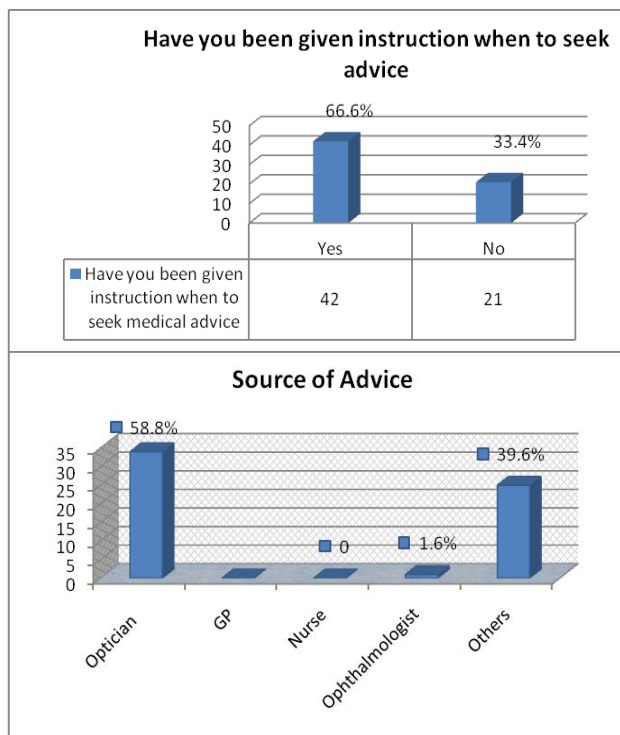
Activities to avoid in contact lens care	Yes	No
Have you ever slept with contact lens	31	32
Have you ever slept with contact lens	26	37
Have you ever slept with contact lens	42	21

In order to have safe usage of the contact lenses, there is a need to adhere to the following recommendations:

- a. Hand washing before and after handling the contact lens.
- b. Daily cleaning and disinfection of the contact lens. The daily cleaning regimen includes
  - i. Preservative free daily cleaner
  - ii. Preservative free saline.
- iii. Cleansing solution containing hydrogen peroxide with a minimum exposure of 4 hours exposure to help destroying acanthamoeba
- iv. Cleaning and disinfection of the contact lens case regularly at least once a week.
- v. Weekly treatment with enzyme tablets (not necessary in disposable lenses replaced every 2 weeks or less)
- c. Wetting solution is dropped on the corneal surface of the lens before it is inserted.
- d. Soaking the contact lens when it is not in use.
- e. Seeking advice as needed from the relevant health professionals.

(Ehlers et al 2008, Stollery et al 2005).

It is important to keep the contact lens users informed regarding the right time of seeking advice, therefore the survey questioned our patients if they would know when to seek advice and the source of information they need to seek advice from as follows



### Recommendations from the audit

1. The need to re-educate users of the care of the contact lenses and demonstrate the correct procedure of inserting and removing the contact lens.
2. Washing hands prior to handling the contact lens and avoidance of creamy soft soaps and ensuring all the trace of cream is removed from the finger tips.
3. The need to discard any remaining solution within 28 days of use
4. Allowing time for the cornea to breathe by removing the contact lenses for a good period of time every day.
5. Saliva and tap water must not be used in wetting the contact lens.
6. Avoid swimming, showering, and washing face while the contact lens is in the eye.
7. Removing the contact lens before going to sleep and using the specified container to place the lens in with the special solution.
8. Removing the contact lens if the eye becomes irritable or red and seeking medical advice as soon as possible.
9. Wetting the cornea with preservative free artificial tears before inserting the contact lens and seeking advice from the doctor or the optician. Additionally, if the soft lens has dried out, they should be discarded and refitted.

### REFERENCES

1. Agarwal, R (1972). "Some Thoughts on Soft Lenses". The Contact Lens 4 (1), p:172-175.
2. Albert, D; Miller,J; Azar,D; Blodi,B. (2008)Principles and Practice of Ophthalmology. Third edition. Philadelphia: WB Saunders.
3. Ambroziak, AM;Szaflik, JP;Szaflik, J. (2004) Therapeutic use of a silicone hydrogel contact lens in selected clinical cases. Eye Contact Lens. 30(1), p: 63-7.
4. Bausch + Lomb PureVision (balafilcon A) Visibility Tinted Contact Lens is indicated for therapeutic use. Use as a bandage contact lens for corneal protection and corneal pain relief during treatment of ocular pathologies as well as postsurgical conditions.
5. Benjamin, L (2009)Training in ophthalmology, the essential curriculum.Oxford University Press.

## Ibrahim/Contact lenses wearing. How much do patients know and how to improve it.

6. Dart, JK; Saw, VP; Kilvington, S; (2009) Acanthamoeba keratitis: diagnosis and treatment update 2009. *Am J Ophthalmol.* 148(4), p: 487-499.
7. Denniston, A and Murray, P (2009) Oxford Handbook of Ophthalmology. second edition Oxford University Press Oxford.
8. Ehler, J; Shah, C; Fenton, G Hoskins, E (2008) The Wills Eye Manual: Office and Emergency Room Diagnosis and Treatment of Eye Disease Paperback. Fourth edition. Philadelphia Lippincott Williams & Wilkins.
9. Farandos, M; Yetisen, K; Monteiro, J; Lowe, R; Yun, H (2014). Contact Lens Sensors in Ocular Diagnostics. *Advanced Healthcare Materials.*
10. Hancu, A; Stanila, A; Mihai, E and Teodoru, A (2011) Indication of the therapeutic contact lenses. *Acta Media Transilvanica Martie* 2(1), p:1-3
11. Heitz, RF and Enoch, J. (1987) "Leonardo da Vinci: An assessment on his discourses on image formation in the eye." *Advances in Diagnostic Visual Optics* 19—26.
12. Kanski, J (2009) *Clinical Ophthalmology: A Synopsis.* Second edition. Butterworth Heinemann - Elsevier Limited. Oxford.
13. Kanski, J and Bowling, B (2011) *Clinical Ophthalmology: a systematic approach.* 7<sup>th</sup> edition. Butterworth Heinemann - Elsevier Limited. Oxford.
14. Krachmer, J; Mannis, M; and Holland, E. (2011) *Cornea, fundamentals, diagnosis and management.* Third edition. MOSBY.
15. Lemp MA, Bielory L; (2008) Contact lenses and associated anterior segment disorders: dry eye disease, *Immunol Allergy Clin North Am.* 28(1), p:105-17.
16. Lim, A; Constable; I, and Wong, T (2008) *Colour Atlas of Ophthalmology.* Fifth Edition. World Scientific Publishing Co. London.
17. Mandell, R (1988) *Contact Lens Practice,* 4<sup>th</sup> Edition. Charles C. Thomas, Springfield, IL.
18. Norina, T.J., Raihan. S., Bakiah, S., Ezanee, M., Liza-Sharmini, A.T., Wan Hazzabah, W.H. (2008) *Singapore Med. Journal* 49 (1), pp. 67-71.
19. <http://www.sciencemuseum.org.uk/broughttolife/people/adolfeugenfick.aspx>
20. <http://www.eyecandys.com/news/finding-the-right-circle-lenses>
21. Pearce, J (2007) "Norman Gaylord, 84; helped develop type of contact lens". (New York Times News Service). *The Boston Globe.*
22. Rhee, D and Pyfer, M (2002) *The Wills eye manual : office and emergency room diagnosis and treatment of eye disease.* Forth edition. Philadelphia. Lippincott Williams & Wilkins.
23. Romero-Jimenez, M., Santodomingo-Rubido, J. and Wilffsohn, J. S. (2010) Keratoconus: a review. *Contact Lens and Anterior Eye* 33p: 157-166.
24. Stollery, S; Shaw, M and Lee, A (2005). *Ophthalmic Nursing.* Third edition. Blackwell publishing.
25. Szaflik, JP; Ambroziak, AM; Szaflik, J. (2004) Therapeutic use of a lotrafilcon A silicone hydrogel soft contact lens as a bandage after LASEK surgery. *Eye Contact Lens.* 30(1):59-62.
26. Szczotka-Flynn, LB; Pearlman, E; Ghannoum, M; Microbial contamination of contact lenses, lens care solutions, and their *Eye Contact Lens.* 2010 Mar; 36(2):116-29.
27. Tananuvat, N., Suwanniponth, M. (2008) Microbial Keratitis in Thailand: a survey of common practice patterns. *Journal of Med. Assoc.* 91(3) p: 316-22.
28. Tsai, J; Denniston, A; Murray, P; Haung, J; and Aldad, T (2011) *Oxford American handbook of Ophthalmology.* Oxford University Press.
29. Wani, M.G. (2010) Guidelines for the Management of Suspected Microbial Keratitis in Settings with Limited Laboratory Facilities. *Southern Sudan Medical Journal,* 1(3), pp.15-20.
30. Yanoff, M, and Duker J (2004) *Ophthalmology.* 2<sup>nd</sup> ed. St. Louis: Mosby