

CASE REPORT: ANESTHETIC MANAGEMENT OF A PATIENT PRESENTING WITH NEUROFIBROMATOSIS TYPE 2.

Dr. Ketki P. Deshmukh¹, Dr. Sarita S. Swami²



*¹Department of Anesthesiology, Bharti vidyapeeth University, Pune, Maharashtra, India.

*² Professor Department of Anesthesiology, Bharti vidyapeeth University, Pune, Maharashtra, India.

ARTICLE INFO

Corresponding Author:

Dr. Ketki P. Deshmukh,
Department of Anesthesiology,
Bharti vidyapeeth University, Pune,
Maharashtra, India.
ketkideshmukh19@yahoo.com



DOI: <http://dx.doi.org/10.15520/ijmhs.2017.vol7.iss3.160>

ABSTRACT

The paper presents the rare case of neurofibromatosis type 2 scheduled for hysterectomy. The 39 year old female patient admitted in obgy department with chief complaint of dysmenorrhea. History of exaggeration of skin neurofibromas after first pregnancy moreover she was operated for vocal cord nodule one year back, presenting with CNS involvement. In this case report we are discussing the anesthetic challenges faced and the multidisciplinary approach required for successful management.

Keywords: Neurofibromatosis type 2, difficult airway, complications.

©2017, IJMHS, All Right Reserved

INTRODUCTION

Neurofibromatosis Type 2 (NF2) is an autosomal dominant disorder characterized by central nervous system (CNS) tumors. A mutated allele of the *NF2* gene on chromosome 22 accounts for this disorder.^{1,2} Tumors are often found throughout the CNS, including the brain and spinal cord, although peripheral nerves may also be involved. The types of tumors involved include schwannomas, meningiomas, ependymomas, and neurofibromas. Schwannomas are benign tumors composed of Schwann cells located outside the nerve and less than 1% become malignant. NF1, or Von Recklinghausen's disease, is an autosomal dominant disorder caused by mutations in the *NF1* gene on chromosome 17, and is characterized by café-au-lait spots and freckles. NF1 is much more common than NF2, having a prevalence of 1 in 2,500-3,500 worldwide while the incidence of NF2 in the general population is 1 in 33,000-40,000, while the prevalence is 1 in 57,000.³ Diagnostic criteria is enlisted in table (1).

Table 1. Diagnostic criteria for neurofibromatosis type 2:

1.	Bilateral vestibular schwannomas (or acoustic neuromas) of nerve VII, confirmed by MRI, CT or histological examination;
2.	A first-degree relative with NF2 and unilateral tumor of nerve VIII.
3.	A first-degree relative with NF2 and any two of the following tumor types: neurofibroma, meningioma, schwannoma, glioma or juvenile posterior subcapsular lenticular opacity.

Case report

The 39 year old female patient admitted in obgy department with chief complaint of dysmenorrhea since 4

months, known case of hypothyroidism and convulsion disorder. She was diagnosed case of NF 2 which shows genetic origin as her mother and siblings also has similar lesions. There is history of increase in number of skin neurofibromas during her first pregnancy i.e. at the age of 25 years. In her past history she has presented with vocal weakness and per oral bleed, for that she underwent Direct laryngoscopy with excision of vocal cord nodules under GA 1 year back, at that time she was evaluated for CNS involvement which showed multiple neurofibromas in brain and spinal cord. After 6 months she had one episode of convulsion for which was started on tablet levetiracetam. In this case report we are discussing the anesthetic challenges faced and the multidisciplinary approach required for successful management.

Physical examination showed multiple neurofibromas more in number on trunk and back as compared to extremities and face. Parameters showed stable hemodynamic status. Spine examination revealed multiple fibromas. On airway examination she was Mallampati grade 2, Indirect laryngoscopy presented bilateral normal and mobile vocal cords.

Routine investigations including hemogram, urine, bsl, ECG along with 2D echo were within normal limit. Few more specific investigations required in this case scenario were done prior to surgery.

MRI Brain studies reported small foci of hyperintensity in right globus pallidus bilateral white matter and left middle cerebellar peduncle and represents hamartomatous lesions of NF1/NF2 (figure 2). HRCT thorax showed no evidence of pulmonary fibrosis/cystic lesion.

Old report of MRI Spine screening was suggestive of multiple enhancing subcutaneous schwannomas no

intraspinal enhancing lesion in cord or meninges .Posterior disc protrusions seen at C5-C6 ,C6-C7 ,L4-L5 AND L5-S1.contrast studies show multiple enhancing subcutaneous schwannomas in dorsal and lumbar region.

MSCT Larynx/ Neck showed Supraglottic, glottis and infraglottic larynx appears normal. Bulky thyroid noted.X RAY CHEST PA view: no significant abnormality noted. USG suggestive of subserosal anterior wall uterine fibroid measuring 6*5*2 cm. No other abnormality noted.

Challenges encountered:

1. Difficulty for regional anesthesia
2. Difficult airway
3. Convulsion disorder

Figure 1 Local cord nodule post excision.

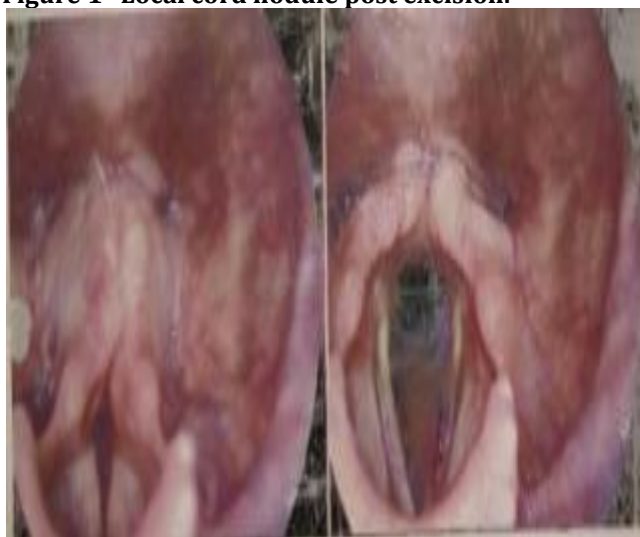
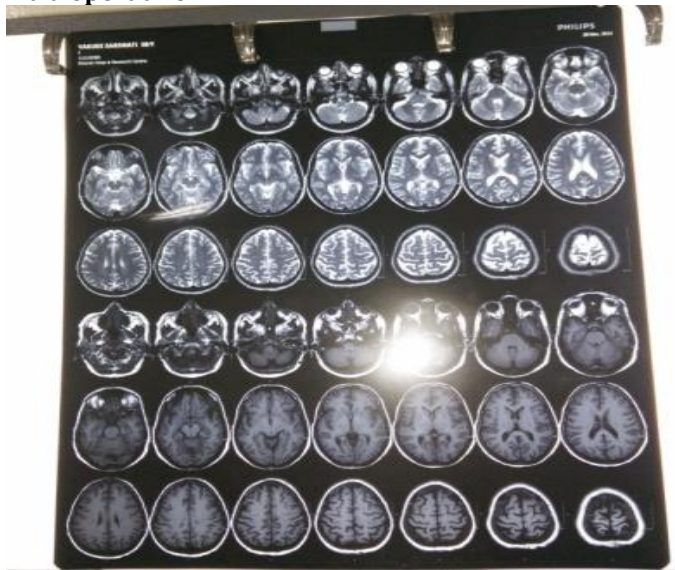

Figure 2: MRI brain showing hamartomus lesions. Intra operative



Considering risk regarding regional anesthesia 1.intra spinal cord lesions, 2.mri brain showing multiple lesions and 3. No space available at spinal region,we opted for general anesthesia. Patient was premeditated with inj. Glycopyrolate 0.2 mg. In operating room premedication of inj. Midazolam 1 mg and injection Fentanyl 50mcg was given.

Induction was done with injection thiopentone sodium 300mg. after check ventilation inj. Rocurium 40mg was given and patient ventilated for 90 seconds. Difficult airway cart was kept ready. On laryngoscopy MCLS grade 1 was noted and patient was incubated with cuffed ETT No.7. Tube placement was confirmed with 5 point auscultation and capnograph.

Maintainace was done by inhalational agent sevoflurane, O2, N2Oand adequate doses of muscle relaxants.Intraoperative fluid was replaced crystalloids according to holiday and sugar formula , intra op blood loss 100 ml and intra op urine output noted 200ml.

Intraoperative patient was monitored closely maintaining SpO2 99%, EtCO2 – 35. Patient reversed and extubated with inj. Neostigmine 2.5 mg and inj.glycopyrolate 0.4 mg IV after fulfilment of extinction criteria . Post extubation on auscultation RS –AEBE clear , SpO2 – 100%.

DISCUSSION

The incidence of NF1 is 1 in 2500-3300 with a prevalence of 1 in 5000, while that of NF2 is less common with birth incidence of 1 in 33,000 -44,000 and prevalence of 1 in 2,10,000^{3,4}. NF2 caused by mutation in Timor suppressor gene on chromosome 22q, encoding protein called Merlin or shwannomin.

Clinical characteristics resulted from vestibular shwannomas (44.4%) , CNS tumors (22.2%) , skin tumors (12.7%) and Café-au-lait spots were noted in 47.5% of patients. Therefore , in NF2 patients full neurological examination and CNS imaging studies are indicated⁴.

Patients with NF2 who underwent operations under General anesthesia are reported in various fields like otolaryngology , neurosurgery , vestibular shwannomas with sensory deafness. At the same time large data is available regarding anesthetic management for patients with NF1 including sensitivity to scolinesas well as non depolarizing muscle blocking agents , difficult airways secondary to neurofibromas in tongue and intraoral structures , chest walk deformity , hypertension, cardiomyopathy , renovascular disease etc¹. Even though presence of such conditions in NF2 Is unknown it would be prudent to maintain high index of suspicion for them and their potential deleterious effects on anesthetic management .

In this case our patient presented potential for difficult airways secondary to history of vocal cord neurofibromain past making General anesthesia difficult. Along with difficulty in airway patient presented great risk for regional anesthesia in view of presence of multiple neurofibromas in CNS and spinal cord . Patient is a known case of convulsion disorder and on treatment since 1 year making regional anesthesia risky. Neuraxialanesthesia is risky in patients with NF2 since intracranial and neuraxial Tumor involvement is a dominant feature.

As our patient presented with history of convulsion showing CNS involvement, neuraxial anesthesia was not favoured and weighing risk benefit ration we opted for General anesthesia. NF2 patients show pulmonary fibrosis and lung tumors not seen in our case scenario. Considering previous airway involvement we kept difficult airway kart ready and we didn't face any difficulty while incubation. When it comes to cardiovascular system hypertension seen as most common manifestation and may also affect the myocardium, our patient didn't present with any such conditions.

CONCLUSION

The neurofibromatosis are a group of conditions which have fundamental implications for the anesthetist, physician and surgeon. NF 1 is most commonly seen as compared to NF2 hence less literature is available on the anesthetic challenges of NF2 .It is very important to have

detailed pathological and clinical knowledge of clinical manifestations of the disease for successful outcome.

REFERENCES

1. Hirsch, N.P., Murphy, A., Radcliffe, J. J. Neurofibromatosis: clinical presentations and anaesthetic implications. *Br J Anaesth.* 2001; 86: 555–564.
2. Uppal, S., Coatesworth, A.P. Neurofibromatosis type 2. *Int J Clin Pract.* 2003;57: 698–703.
3. Sakai T, Vallejo MC, Shannon KT. A parturient with neurofibromatosis type 2: anesthetic and obstetric considerations for delivery. *International journal of obstetric anesthesia.* 2005 Oct 31;14 (4):332-5.
4. Parry D M, Eldridge R, Kaiser-Kupfer M I, et al. Neurofibromatosis 2 (NF2): clinical characteristics of 63 affected individuals and clinical evidence for heterogeneity. *Am J MedGenet* 1994; 52: 450–461
5. Asthagiri AR, Parry DM, Butman JA, Kim HJ, Tsilou ET, Zhuang Z, Lonser RR. Neurofibromatosis type 2. *The Lancet.* 2009 Jun 12;373(9679):1974-86.
- 6.. Esler M D, Durbridge J, Kirby S. Epidural haematoma after dural puncture in a parturient with neurofibromatosis. *Br J Anaesth* 2001; 87: 932–934.
7. Mendel T, Wierzba-Bobrowicz Te, Skarżyński H, Stępień T, Członkowska A. Neurofibromatosis type 2: case report.