

## Functional and Aesthetic Evaluation of Finger Injuries

Dr. Vaibhav Jain<sup>1\*</sup>, Shivi Jain<sup>2</sup>, Pradeep Jain<sup>3</sup>, Tibar Banerjee<sup>4</sup>

<sup>1</sup>Department of Plastic Surgery, IMS, BHU

<sup>2</sup>Department of Radiodiagnosis and Imaging, IMS, BHU

<sup>3</sup>Department of Plastic Surgery, IMS, BHU

<sup>4</sup>Department of Plastic Surgery, IPGMER and SSKM Hospital, Kolkata

DOI: <https://doi.org/10.15520/ijmhs.v9i7.2654>

Accepted 20 Jul 2019; Received 1 Jul 2019; Publish Online 31 Jul 2019

Reviewed By: Dr.  
Daniel V.  
Department: Medical

### ABSTRACT

Finger injuries are one of the common problems presenting in any plastic surgery emergency and are often neglected [1]. Here we share our experience of treating finger injuries in the setting of a tertiary care centre in government sector in India. We managed 50 patients in our hospital and did various surgical (split thickness skin graft, flaps) or non-surgical procedures on the patient's according to the patient demand and situation. Healing by secondary intention was best for small wounds of less than 1cm<sup>2</sup>, in terms of cosmesis and function. Local advancement flaps proved better for larger wounds.

**Keywords:** Finger injuries, STSG(split thickness skin graft), flaps, healing, wounds

\* Corresponding author.

†Email: [vjain3112@gmail.com](mailto:vjain3112@gmail.com).

### Introduction:

Fingers are the most common part of the human body that are often involved in daily activities, making them vulnerable to trauma [1]. For reconstruction of soft tissue defects of fingers one need to plan carefully for replacing the tissue not only with good color and texture match but also restoring the padding, sensations and aesthetics.

Treatment options vary from the simplest conservative treatment to the most sophisticated microsurgical reconstruction.

The present study is an attempt to focus on the merits and demerits of various procedures that are commonly employed in an emergency set-up in our hospital setting for soft tissue defects of fingers.

### **Aims and objectives of the Study:**

The aim of the study was to evaluate functional and aesthetic recovery of an injured finger in relation to the reconstructive method used.

### **Materials and methods:**

A prospective study consisting of 50 patients with finger trauma was carried out and in total 63 fingers was treated. Non-consenting patients, patients with extremes of age (<1 year and > 70 years) and medical conditions like diabetes mellitus and co-existing malignancy were excluded. Detailed history and examination were done with evaluation of physical defect and functional deficit. Patients were offered different surgical choices according to the tissue defects. Informed consent of the patient was taken. Post-operative outcomes in terms of aesthetic and functional outcomes were evaluated. Patients were followed over a period of 12 months in the outpatient department.

Functional outcome was evaluated under 5 subheads: Tactile sensation, Two-point-discrimination, Cold sensation, Heat sensation and Pain sensation at 12 months.

Calipers were used to assess Two Point Discrimination. The patients were initially instructed to keep their hands still and close their eyes. The site was stimulated proximally to distally, followed by a gradual decrease in the distance of the detector points. The procedure was repeated with decreased distance until the patients were unable to distinguish the two separate stimuli. The shortest distance was recorded. The test was performed at 12 months. Values up to 7 mm were considered as normal while values equal to or more than 8 mm were considered as sensory deficit. Pain sensation detection was performed by lightly puncturing the skin with a 2 ml syringe needle. Temperature sensation was evaluated by touching the skin with two test tubes, one of which was filled with cold water (0-10°C) and the other with hot water (50-

60°C). [2]

Aesthetic outcome was evaluated in terms of patient satisfaction. Patient was asked about the appearance of operated site at 12 months and responses were classified into 5 categories: Satisfied with the appearance and agree with that (5), Mostly satisfied with the appearance but feels uncomfortable at times (4), Feels that appearance of the fingers uncomfortable socially most of the time (3), Feels that appearance of the fingers made him socially uncomfortable (2), Appearance of the hand made him depressed (1) [Modified from Michigan Hand Questionnaire;3]

### **Statistical analysis**

For statistical analysis, the data was analyzed by SPSS 20.0.1 and Graph Pad Prism version 5. Unpaired proportions were compared by Chi-square test or Fischer's exact test. A p-value < 0.05 was considered as statistically significant.

### **Observations and results**

The majority of the patients (36%) belonged to 31-40 years age group with significant male predominance among the patients (68% vs 32%). Only 6% patients were >60 years in age.

Injury patterns were divided into Crush injury, Cut injury and Degloving injury. 24 patients sustained Crush injuries making it the most common pattern in the study (48%).

Crush injuries were mostly sustained due to occupational causes involving working with heavy machines and Road traffic accidents. 15 patients sustained Cut injuries (30%), common causes of which were cut due to high speed rotating fan at home or workplace and during work in kitchen. Degloving injury was found in 11 patients (22%), commonest cause being road traffic accident and ring degloving.

Middle finger was most commonly involved (33.3%) finger in the trauma. Index finger

(30.2%) was next followed by ring finger (22.2%) and little finger (14.3%).

There were 36 deep wounds in which bone or tendon or both were exposed [Table 1]. They comprised 57.1% of total cases and in these cases

various local flaps were done. Of the 27 superficial wounds 14 (22.2%) were smaller than 1cm<sup>2</sup> and were left for healing by secondary intention. Of the remaining 13 wounds (20.7%), which were larger than 1cm<sup>2</sup>, split thickness skin graft was applied.

**Table 1: Depth of wounds over fingers and the coverage options used**

Depth	Number	Coverage of wounds	Percent
Deep wounds with exposed tendon and/or bone	36	Local Flaps	57.1%
Superficial small wounds (<1 cm <sup>2</sup> )	14	Healing by secondary intention	22.2%
Superficial large wounds (>1cm <sup>2</sup> )	13	Grafts	20.7%
Total	63		100.0%

Volar V-Y advancement (33.3%)(Fig 1) and Kutler (lateral V-Y advancement)(33.3%)(Fig 2) were the most common flaps done in the

study followed by cross-finger flaps (22.2%)(Fig 3) and Homodigital (5.6%) and Oblique V-Y advancement flaps (5.6%)[Table 2].

**Table 2: Various flaps done during study**

Flaps Done	Number	Percent
Cross finger flaps	08	22.2%
Homodigital (Reverse)	02	5.6%
Kutler flaps (B/L V-Y advancement)	12	33.3%
Oblique V-Y advancement flaps	02	5.6%
Volar V-Y advancement flaps (Kleinert )	12	33.3%
Total	36	100.0%

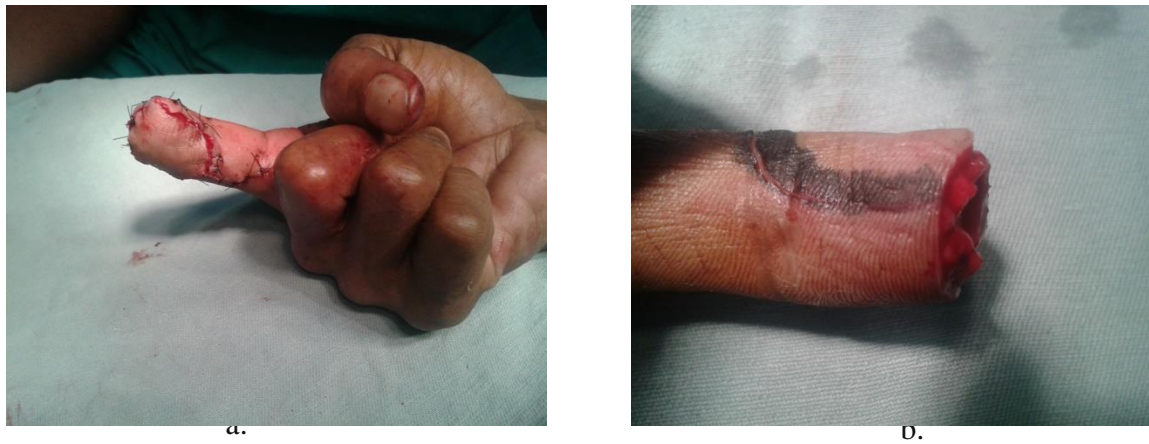

Figure 1: a. Right index finger injury; b. Volar V-Y flap in situ

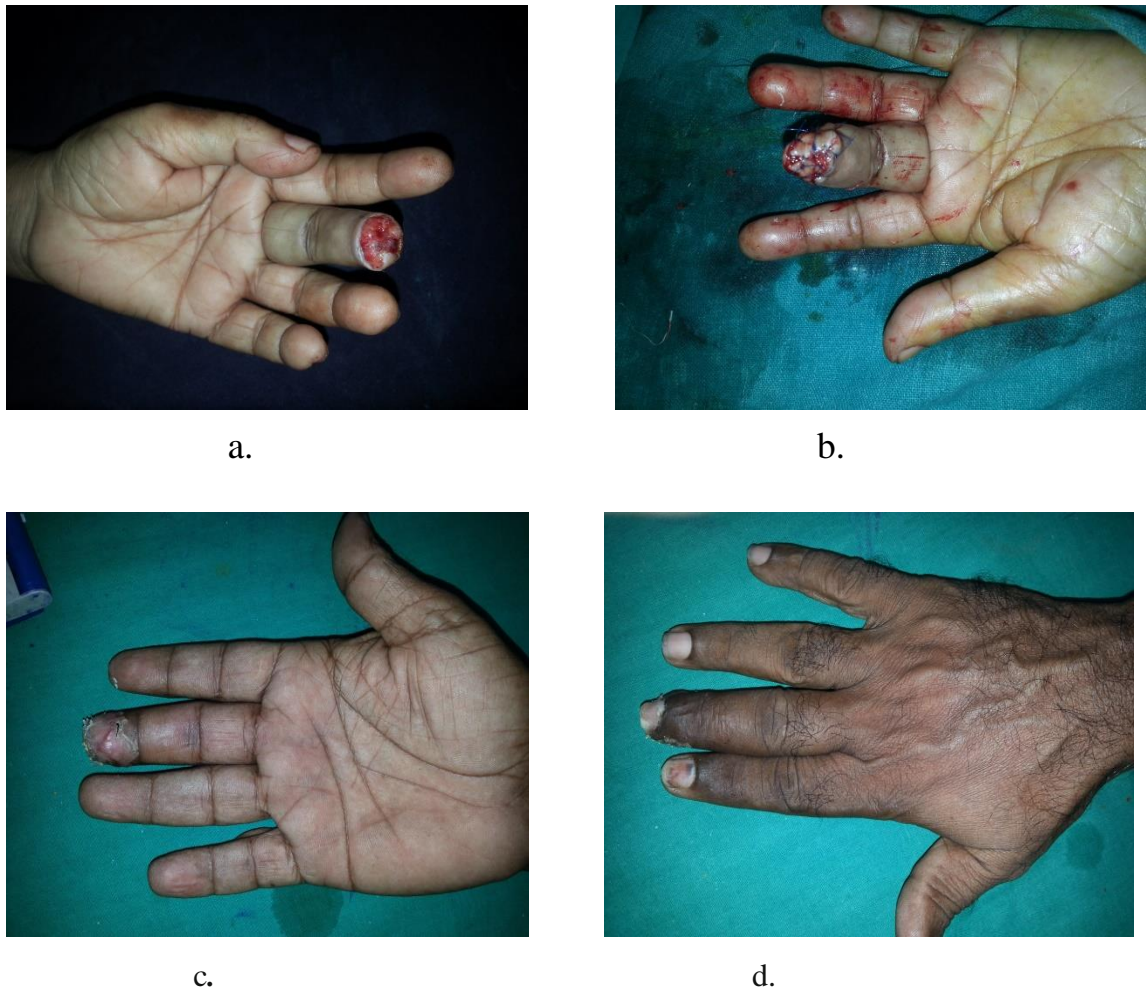
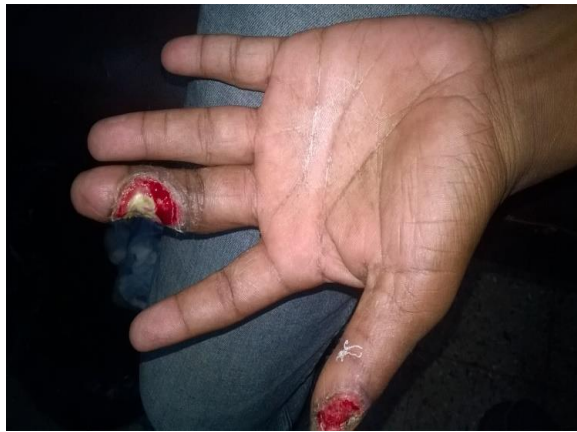
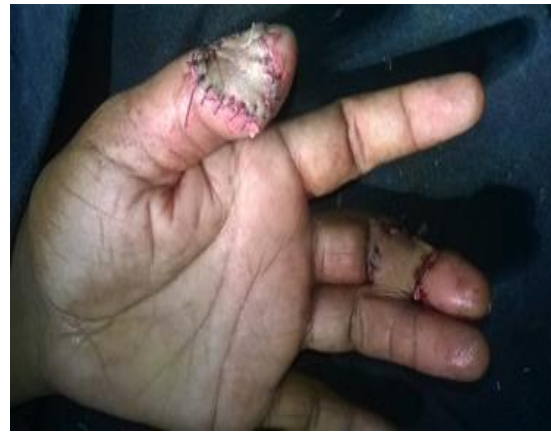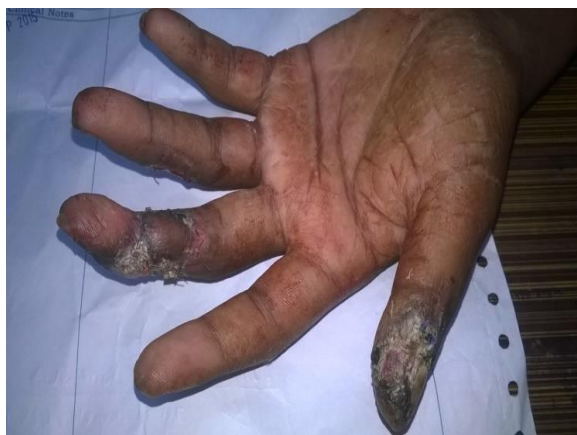Figure 2: a. Left middle finger injury; b. Kutler flap in situ; c. Healing at 21 days (Palmar aspect); d. Healing at 21 days(dorsum)



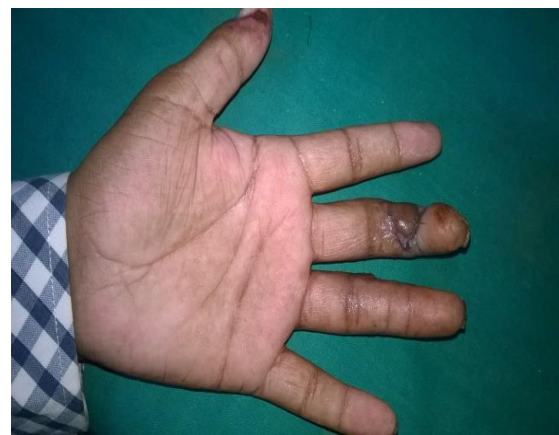a.



b.



c.



d.

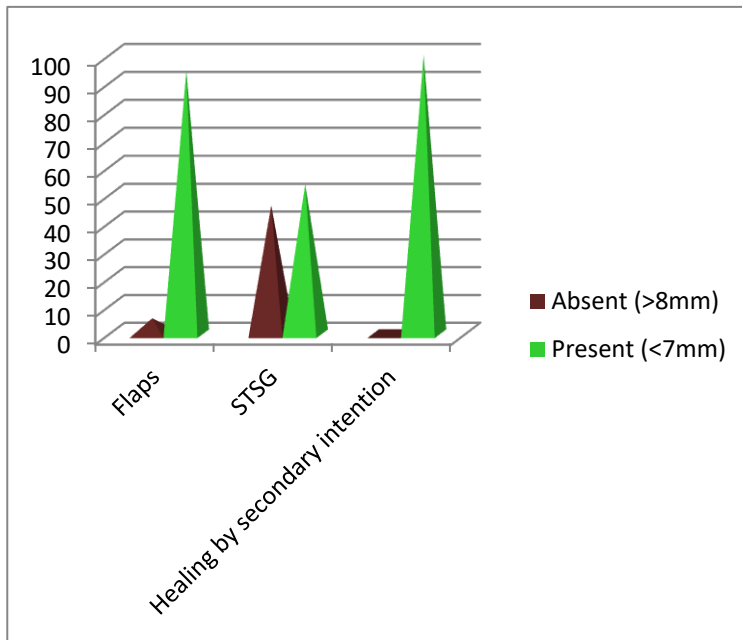
**Figure 3:**

- a. Old crush injury of left middle finger and thumb**
- b. Cross finger flap for exposed bone on volar aspect of left middle finger with raw area on thumb skin grafted.**
- c. Flap after one week of detachment**
- d. Flap after one month of detachment**

Tactile sensation was present in all the fingers at the end of 12 months irrespective of the treatment option used.

Evaluation of Two-Point Discrimination test revealed that out of 36 flaps, 2 cross finger flaps (5.6%) showed the test negative, while it was positive in the rest at the end of 12 months. In

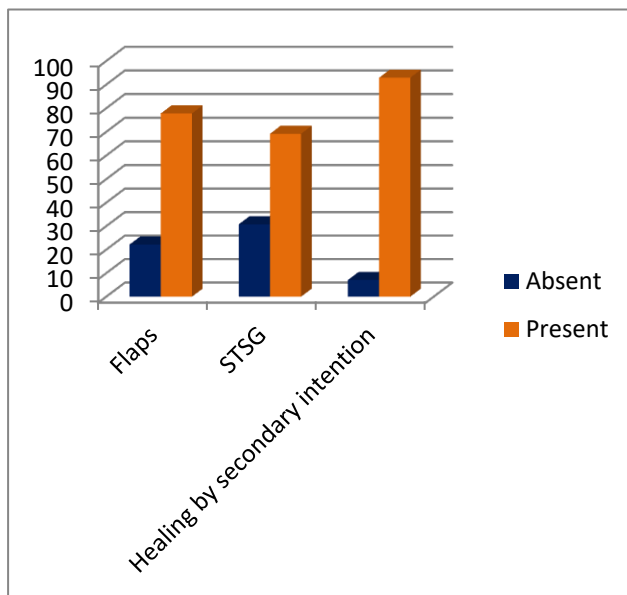
patients where skin grafting was done, 6 out of 13 (46.2%) showed absent Two-Point-Discrimination. Two-Point Discrimination was positive in all patients in which healing by secondary intention was preferred [Fig 4].



**Figure 4: Return of Two-point discrimination at the end of 12 months**

It was found that 28 flaps (77.8%) had their Pain sensation returned at the end of 12 months, while in 8 flaps (22.2%) it didn't return. Of these flaps 5 (3.8%) were cross finger flaps and 3 (8.3%) were

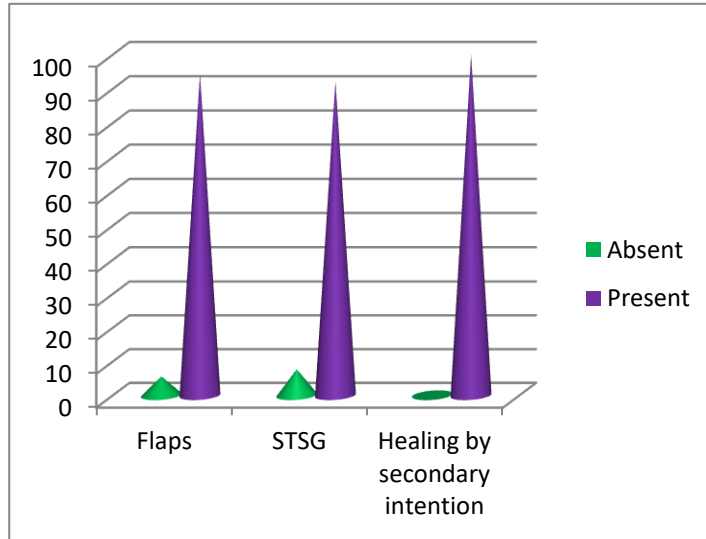
Kutler flaps. 4 STSG (30.8%) showed failure in return of pain sensation. Only one patient, an old lady (7.1%) showed no return of pain sensation when allowed to heal secondarily. [Fig 5]



**Figure 5: Return of pain sensation at 12 months**

Most of the flaps showed return of cold sensation at 12 months, however 2 flaps (5.6%), one cross finger and another Kutler flap failed to do so. Out of 13 STSG only one (7.7%) wasn't able to

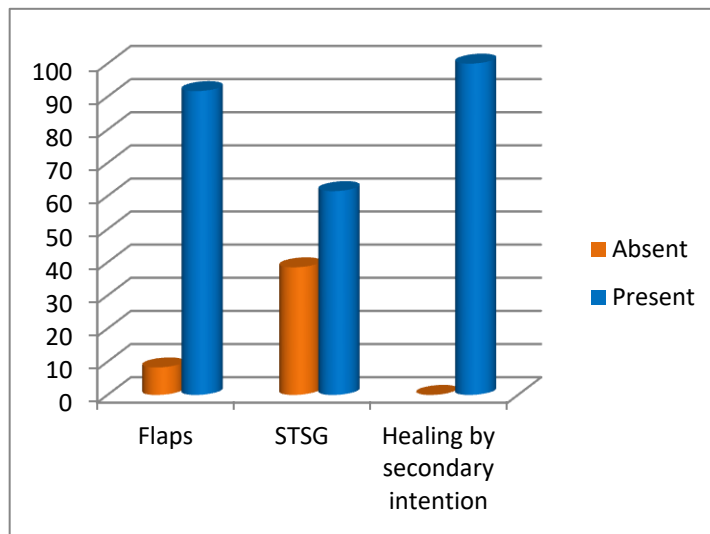
perceive cold sensation while all the patients who allowed healing by secondary intention were able to perceive cold [Fig 6]



**Figure 6: Return of cold sensation at 1 year**

Only 3 flaps (8.3%) failed to recover sensitivity to heat at 12 months and all of them were Cross-finger flaps. Heat sensation was absent in 38.5% of STSGs (5 patients). Sensitivity to heat as with

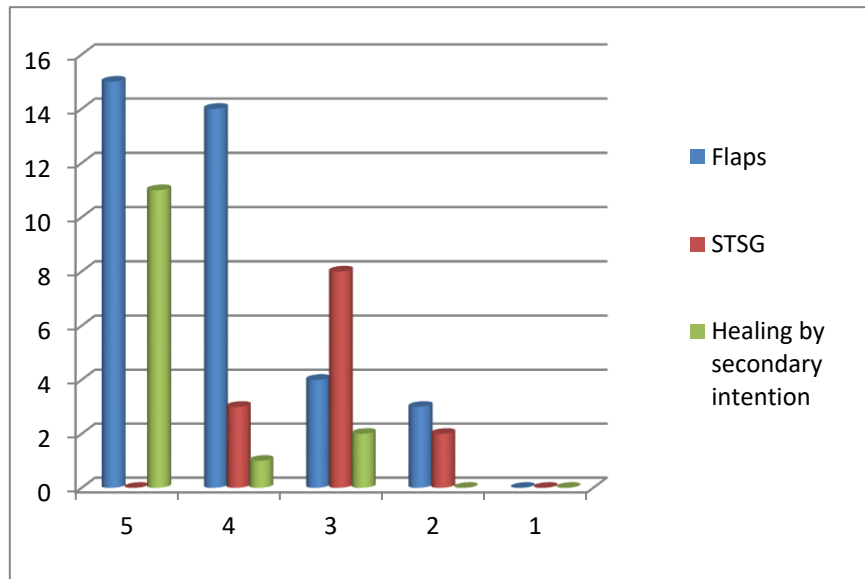
cold returned in all the patients with secondary intention healing [Fig 7].



**Figure 7: Return of Heat sensation at 1 year**

Most of the patients with resurfacing by flaps were satisfied with the appearance (80.5%). A shade better than the patients with healing by secondary intention, which also showed high satisfaction (85.7%). However, only 3 (23.07%) patients with STSGs, were satisfied with the final

result. All the patients with Volar V-Y advancement and Kutler flap were satisfied with the final appearance, whereas appearance of fingers in most of the patients with Cross-finger flap (06 patients, 75%) made them uncomfortable socially.[Fig 8]



**Figure 8: Aesthetic appearance of fingers for the various methods used at 12 months**

There were only few complications. Surgical site infection (SSI) was the most common problem, it occurred in 5 patients and was managed conservatively and 1 Volar V-Y advancement flap required resuturing after controlling surgical site infection. In 3 superficial wounds which we allowed to heal secondarily, got infected and needed dressing. There was marginal flap necrosis in 3 patients who responded well to **Table 3- Complications arising during study**

conservative treatment. There was partial STSG loss in 1 patient of Cross-finger flap, which was managed conservatively. There was donor finger stiffness in 1 patient of Cross-finger flap, which required Physiotherapy. There was complete STSG loss at donor site in 1 patient of Cross-finger flap, which required regrafting of skin.[Table 03]

	Complications	Number	Management
1.	Wound infection	03 - Superficial small wounds (<1 cm <sup>2</sup> )	Managed conservatively with dressing
2.	Marginal flap Necrosis	Kutlerflap(02)	Managed conservatively with dressing
		Volar V-Y advancement flap (01)	
3.	Surgical site infection	05	Managed conservatively with dressing
		01	Resuturing of Volar V-Y advancement flap
4.	STSG loss at donor site	01(Cross-finger flap)	Reapplication of STSG
5.	Donor finger stiffness	01(Cross-finger flap)	Physiotherapy
6.	Partial STSG loss	01(Cross-finger flap)	Managed conservatively with dressing
7.	Hyperaesthesia	01(Skin graft)	Oral analgesics

**Discussion:**

Injuries that cause soft tissue defects of fingers threaten its function and viability. The ideal tissue

for volar defects of the digits should bring in glabrous and sensate skin supple enough so as not to interfere with motion of the joints.



In this prospective study consisting of 63 injured fingers in 50 patients, majority of the patients were in the fourth decade of life reflecting the vulnerability of the people in this age group because of various occupations. Males were affected approximately two times more than their female counterparts.

Small and superficial defects  $<1\text{cm}^2$  may be left to heal on their own by secondary intention taking care of secondary infection [2,3]. The defects  $1-2\text{cm}^2$  in size may be skin-grafted or covered by volar, oblique or lateral (unilateral/bilateral), V-Y advancement flap or Homodigital flaps [4,5,6]. For the medium to large defects, pedicled homodigital or heterodigital flaps from the palm may sometimes be inadequate, limited in reach or compromise the function and cosmesis of the donor digits, so arise the need of distal or free flaps. Free flaps have the advantage of providing tissue of desired quality with quantity [7].

The soft tissue defect in a digit may be due to variety of causes. Whereas Sun et al had most of the digital soft tissue defects because of the crush injury (6 fingers) followed by electric saw (5 fingers) and burnt scar removal (4 fingers) among 13 patients [8], Zhang et al also had maximum patients due to crush injury followed by pressing injury, cutting injury and avulsion injury in that order [9]. Similarly in our patients, crush injury was the most frequent cause (48%) followed by cut (30%) and degloving (22%).

Defects  $>1\text{cm}^2$ , without exposure of underlying tendon/bone, may be skin grafted [10]. For non-graftable defects, various flaps have been described for resurfacing, each with its own limitations in terms of colour, texture, bulk, sensations and donor site morbidity. Whereas secondary healing for soft tissue defect  $<1\text{cm}^2$  provides 90% 5-year satisfaction, skin grafting yields 50% 5-year satisfaction and most remain painful. Davis et al found split thickness skin grafts to have impaired cutaneous vasodilation

and sweating even 9 months after surgery [11].

The choice of flap depends on the site and surface area of the skin defect and the injuries of adjacent digits. Out of various flaps used in the present study, the most frequently used were Kutler's (33.3%), Atasoy's (33.3%) and Cross-finger (22.2%). Oblique V-Y advancement flap and Homodigital flaps were used in two instances each. The limitations of V-Y advancement flaps are little advancement (1cm) and long term tenderness and hyperaesthesia. They also leave too much tension on the vessels. Their advantage is presence of local skin with similar colour, texture and sensibility with single-stage procedure and primary closure of donor site. Cross-finger flaps are two-stage procedure, often resulting into finger stiffness and not suitable in patients above 40 years of age. While executing them, one needs to preserve paratenon over extensor tendon and it requires full-thickness skin graft to the donor site. [12]

Kuang-Wen et al (2015) demonstrated utility of multilobed posterior interosseous artery perforator flap for multi-finger skin defects [13]. Multi-finger soft tissue defect resurfacing has always been a challenge for hand surgeons. The traditional method to manage such multiple defects is to use multiple local island flaps, combination of grafts and flaps for different sites; an abdominal flap with syndactylization and separation of digits at a later stage. However, it is not only a two-stage procedure but also bulkier and less sensate compared to other options.

When a finger defect is managed, not only adequacy of soft tissue but sensory recovery in flaps and their aesthetic appearance is also evaluated. Moberg compared a hand without feeling to a hand without a purpose [14]. The loss of sensory function in hand is liable to affect the perceptive function of the hand and makes it more vulnerable for injury.

The recovery of sensations in our patients

depended on various somatic sensations studied and the nature of the tissue replaced. Whereas tactile sensation was present in all the patients where skin graft was used at 6 months, two-point discrimination was  $>8\text{mm}$  (absent) in 46% of the patients. Similarly, pain sensation could recover in 69%, cold in 92% and heat in 61.5% of the patients at 6 months post-operatively. Interestingly, the sensory recovery in all those patients who had wound of  $<1\text{cm}^2$  and were left to heal by secondary intention was remarkable and thus justified use of non-operative modality for such instances.

Skin grafts have decreased number of mechanoreceptors in contrast to flaps that retain their blood supply as well as greater number of sensory receptors [15]. Thus grafting a wound with skin may be a simple procedure but the local flaps have superior sensibility and aesthetic appearance. They also have better options in terms of blood flow and two-point discrimination [16].

Nerves grow into skin grafts from wound margins and the graft bed [17]. The timing of neural invasion and disposition of nerves within a skin graft vary according to the graft thickness and recipient site. Human skin grafts begin to show sensory recovery at 4–5 weeks postgrafting, but occasionally sensation is delayed for up to 5 months. The return of normal sensation is usually complete by 12–24 months. The extent of reinnervation depends on how accessible the neurilemmal sheaths are to the invading nerve fibers—ie, most accessible in fullthickness grafts and least accessible in thin splitthickness grafts. Skin grafts are initially hyperalgesic and slowly regain normal sensation [18]. If skin graft healing is uneventful, the results of two-point discrimination testing will be very close to that of normal skin. Other sensations do not recover so well. Waris and associates [17] measured the thermal sensitivity of 22 split skin grafts transplanted 1–4 years earlier. Cold sensitivity

was present in 14, warmth in 6, and heat–pain in 8 grafts. If the warmth sensibility had recovered, the threshold was lower than for cold. Seven grafts showed no thermal sensibility at all. Haro and colleagues [19] also confirmed poor return of sensitivity in grafts by means of immunohistochemical methods. Grafts less than 7 months old showed no sensitivity whatsoever, and pain sensation had developed only in the 15-month-old grafts. Although deep and superficial nerve plexuses regenerated, no sensory corpuscles were detected in grafted skin at any time. Stella et al [20] independently verified these findings and speculated that the failure of regeneration of sensory corpuscles may be related to the degeneration of periaxonal corpuscular elements.

It is important to realize that the free nerve endings detect pain sensation, tactile corpuscles for tactile sensation, Pacinian corpuscles for pressure and Krause corpuscles for temperature sensation. The static two-point discrimination test determines the density and function of Merkel cell-axon complex. So one can realize that the regeneration of the receptors is very much required for sensory recovery [21].

Ya-Dong et al [2] found restoration of pain, touch and temperature sensations as well as the two-point discrimination in all flaps with flap-sensation function score of S3+ in the sixth post-operative month and could not find any statistically significant difference in sensation between the proximal or peripheral area and the centre of the flap. They also found that the sensory recovery, time of the flap was closely associated with the thickness of the flap.

That the locoregional flaps are quite sufficient to deal with small and medium sized soft tissue defects of the fingers is amply proved by the present study where only few complications arose following such procedures. None of the patients in this study required any major surgical

intervention and most of the wounds with complications responded to conservative measures.

Aesthetic appearance of the fingers following injury plays a crucial role in psychosocial rehabilitation of the patients. Most of the patients in our study, who were not happy with their final results, were those who had undergone skin grafting, but only 8.3% of the patients with flaps were socially uncomfortable. Even those who had superficial small wounds left to heal with secondary intention were quite satisfied with the final appearance and return of sensations. This supports the current therapeutic approach of leaving the wounds  $<1\text{cm}^2$  at the fingertips to heal secondarily. Among the various flaps used, the maximum number of the patients who were well satisfied were those who underwent volar V-Y advancement flap. On the contrary, the maximum numbers of the patients with cross-finger flaps were socially uncomfortable. Thus this study, though small in sample size, also indicates that the choice of the flap for a given instance should be made after properly explaining it to the patient.

### Conclusion:

Finger  $\leq 1\text{cm}^2$  are best managed with non-surgical intervention. Larger wounds have better functional and aesthetic outcome with local flaps such as V-Y advancement, Kutler etc.

### References:

1. Sorock GS. Acute traumatic occupational hand injuries: Type, location, and severity. *J. Occup. Environ. Med.* 2002; 44: 345.
2. Yu YD, Zhang YZ, Bi WD and Wu T. Functional sensory function recovery of random-pattern abdominal skin flap in the repair of fingertip skin defects. *Experimental and Therapeutic Medicine* 2013; 5: 830-4.
3. Chung KC, Pillsbury MS, Walters MR, Hayward RA. Reliability and validity testing of the Michigan Hand Outcomes Questionnaire. *J Hand Surg Am.* 1998 Jul;23(4):575-87.
4. Mennen U and Wise A. Fingertip injuries management with semioclusive dressing. *J. Hand Surg. (Br.)* 1993; 18: 416.
5. Ipsen T, Frandsen PA and Barfred T. Conservative treatment of fingertip injuries. *Injury* 1987; 18: 203.
6. Rohrich RJ and Antrobus SD. Volar advancement flaps. In W. F. Blair (Ed.), *Techniques in Hand Surgery*. Baltimore: Williams & Wilkins, 1996. Pp. 39–47.
7. Jeon BJ, Yang JW, Roh SY, Ki SH, Lee DC, Kim JS. Microsurgical reconstruction of soft-tissue defects in digits. *Injury* 2013; 44(3): 356-6073.
8. Sun W, Wang Z, Qiu S, Gaun S, Hu Y, Zhu L, Liu P. Repair of soft-tissue defects on volar aspect of fingers with medial plantar venous flap. *Chin J Repair and Reconstr Surg* 2010; 24(1): 50-2.
9. Zhang W, Zhang W, Jiao C, Liu Y. Repair of finger soft-tissue defect with island flap based on vascular chain of cutaneous branch of dorsal metacarpal artery. *Chin J Repair and Reconstr Surg* 2013; 27(4): 440-2.18.
10. Holm A and Zachariae L. Fingertip lesion: An evaluation of conservative treatment versus free skin grafting. *Acta Orthop. Scand.* 1974; 45: 382
11. Davis SL, Shibasaki M, Low DA et al. Impaired Cutaneous Vasodilation and Sweating in Grafted Skin During Whole-Body Heating. *J Burn Care Res.* 2007; 28(3): 427–34.
12. Nishikawa H and Smith PJ. The recovery of sensation and function after cross-

- finger flaps for fingertip injury. *J. Hand Surg. (Br.)* 1992; 17: 102
13. Li KW, Liu J, Liu MJ, Xie SL, Liu CX. Free multilobed posterior interosseous artery perforator flap for multi-finger skin defect reconstruction. *J Plast Reconstr Aesthet Surg.* 2015; 68: 9e-16
  14. Polatkan S, Orhun E, Polatkan O, Nuzumlali E and Bayri O. Evaluation of the improvement of sensibility after primary median nerve repair at the wrist. *Microsurg* 1998;18 : 192-6
  15. Chow SP and Ho E. Open treatment of fingertip injuries in adults. *J. Hand Surg. (Am.)* 1982; 7: 470
  16. Schliephake H, Schmelzeisen R, Neukam FW. Long-term results of blood flow and cutaneous sensibility of flaps used for the reconstruction of facial soft tissues. *J Oral Maxillofac Surg* 1994;52 :1247-52.
  17. Waris T, Astrand K, Hamalainen H, et al. Regeneration of cold, warmth and heat-pain sensibility in human skin grafts. *Br J Plast Surg* 1989; 42: 576.
  18. Grabb WC. Basic techniques in plastic surgery (skin grafts). In: Grabb and Smith's Plastic Surgery, 3rd ed, Boston, Little Brown, 1979
  19. Haro JJ, Del Valle ME, Calzada B, et al. Human glabrous skin autografts partially reinnervated without sensory corpuscles. An immunohistochemical study. *Scand J Plast Reconstr Hand Surg* 1994; 28: 25.
  20. Stella M, Calcagni M, Teich-Alasia S, et al. Sensory endings in skin grafts and scars after extensive burns. *Burns* 1994; 20: 491
  21. Ackerley R, Carlsson I, Wester H, Olausson H, Backlund Wasling H. Touch perceptions across skin sites: differences between sensitivity, direction discrimination and pleasantness. *Front Behav Neurosci.* 2014 Feb 19;8:54. doi: 10.3389/fnbeh.2014.00054. PubMed PMID: 24600368; PubMed Central PMCID: PMC3928539.

#### AUTHOR BIOGRAPHY

**Dr. Vaibhav Jain**, Department of Plastic Surgery, IMS, BHU

**Shivi Jain**, Department of Radiodiagnosis and Imaging, IMS, BHU

**Pradeep Jain**, Department of Plastic Surgery, IMS, BHU

**Tibar Banerjee**, Department of Plastic Surgery, IPGMER and SSKM Hospital, Kolkata