



RESEARCH ARTICLE



An analytical Study of Diameter and Depth Morphometry in Human Acetabulum

Dr. Sangeeta Khare¹ | Dr. Yogita Kanwar^{2*}

¹Assistant Professor , Department of Anatomy , Pt JNM Medical College , Raipur (CG)

²Assistant Professor , Department of Anatomy , Late Shri Lakhiram Agrawal Memorial Government Medical College , CG, India.

Abstract

Introduction : Anatomy of proximal femur and acetabulum are very important in total hip replacement surgery. The objective of this study is to compare AD and Depth morphology in humans in terms of age and gender. . Multiplanar evaluation by computed tomography (CT) scan is the key to assess acetabular depth, version, and inclination.

Methods: In this retrospective Radiology based study, AD and Depth measurements of 100 randomly selected CT scans from patients who had come for diagnosis in the Nearby randomly selected Secondary and Tertiary care Hospitals and Radiological Diagnostic centres The patients with surgical intervention, those with an orthopedic problem and those who had undergone acetabular dysplasia and hip arthroplasty were excluded. AD and Depth were performed unilaterally, from the left side.

Results: Measurement results showed that AD was 61.38 ± 3.41 mm in males & 58.25 ± 2.72 mm in females. Average depth was 19.01 ± 2.84 mm in males, & 18.27 ± 1.74 mm in females. Statistically significant difference was found between males and females in terms of AD , while no differences were found in terms of Depth. Correlation analysis results did not show a statistically significant correlation between AD and Depth ($p > 0.05$).

Conclusions : The results of our study will contribute to studies about hip arthroplasty applications. In addition, we believe that a data base will be formed about this subject related with our region.

Keywords: Acetabular Diameter, Hip Bone, CT Scan, Morphology

Copyright : © 2020 The Authors. Published by Publisher. This is an open access article under the CC BY-NC-ND license (<https://creativecommons.org/licenses/by-nc-nd/4.0/>).

1 | INTRODUCTION

Hip joint is one of the most important weight carrying joints of the body. Originally, hip joint was referred to as ball and socket joint; however, it is being referred to as rotational condroids at the moment (1). Acetabulum is the name given to the concave on the medial side of the hip joint (2). In healthy people, head of the femur meets with this concave (3).

Acetabulum is formed from the os ilium, os ischium and os pubis parts of os coxae. The lower part of acetabulum which is not in the shape of full circle ends with inc. acetabuli. This incisura continues upward with fossa acetabuli and the half-moon shaped surface between inc. acetabuli and fossa acetabuli which is called facies lunata is the part that meets the head of the femur (4, 5). At the centre of the joint that is in the lower and mid part of inguinal ligament head of the femur forms a joint with the cup shaped acetabulum (6). This joint enables us to make flexion, extension, adduction and abduction moves (7). Environment and ethnic factors cause changes about acetabulum morphology (8, 9).

Hip joint osteoarthritis is common and it has different etiologies. An incongruous joint is more inclined to the development of degenerative changes than a normal joint anatomy (10). Hip osteoarthritis is estimated to be caused by acetabular dysplasia with a rate of 25-40%. Hip with dysplasia is also associated with acetabular depth (11). It is clinically important to have clear parameters that reflect our society about acetabulum morphology in hip arthroplasty applications, approaches to hip fracture and hip dysplasia (12). The acetabular morphology has shown to differ among different regions of the world. Multiplanar evaluation by computed tomography (CT) scan is the key to assess acetabular depth, version, and inclination at the same time which have been rarely explored.

Anatomy of proximal femur and acetabulum are very important in total hip replacement surgery. The objective of this study is to compare AD and Depth morphology in humans in terms of age and gender.

2 | METHODOLOGY

In this retrospective Radiology based study, AD and Depth measurements of 100 randomly selected CT scans from patients who had come for diagnosis in the Nearby randomly selected Secondary and Tertiary care Hospitals and Radiological Diagnostic centres of Raipur & Bhilai districts. We took valid consent from the Incharge to see the records of the patients from Medical Records Section of selected diagnostic centres with the disclosure that we will use the data for study purpose only. The study was conducted within ethical standards. Medical record numbers were used to generate the data for analysis. The study was conducted within ethical standards & doesn't involved any direct Intervention to any mentioned subjects nor any physical Examination was performed. Randomization was done using computer tables in selecting data.

Males and females between the ages 18 to 45 were included in the study. Males's average age in years was 27.43 ± 4.79 , while females's average age in years was 29.17 ± 5.61 .

Care was taken for the female and males included, not to have any problems about the lower extremity. CTs of patients who had been admitted to hospital for an abdominal problem were used in the study. The patients with surgical intervention, those with an orthopedic problem and those who had undergone acetabular dysplasia and hip arthroplasty were excluded. AD and Depth were performed unilaterally, from the left side (Figure 1).

AD; Acetabular diameter is the name given to the distance between the acetabular ridge nearest to the body of ischium and anterior iliac margin converging the acetabular ridge. Depth; Across the diameter of

Supplementary information The online version of this article (<https://10.15520/ijmhs.v10i04.2859>) contains supplementary material, which is available to authorized users.

Corresponding Author: *Dr. Yogita Kanwar*
Assistant Professor, Department of Anatomy, Late Shri Lakhiram Agrawal Memorial Government Medical College, CG, India.

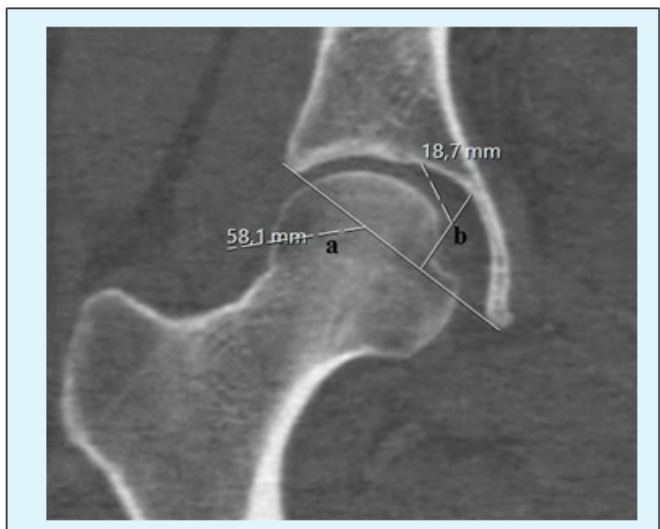


FIGURE 1: Measurements over CT; a: AD, b: Depth.

the acetabulum, a thin metallic strip was placed (9).

Statistical Analysis

The data obtained were analyzed in detail using the statistical software IBM SPSS 22 for Windows 10. Data are reported as mean ± SD or proportions and 95% confidence intervals. Statistical analysis was performed by tests of significance and p-value < 0.05 was considered statistically significant. Shapiro-Wilk test was used to analyze whether the data were normally distributed. Mann-Whitney U test and Spearman Correlation Analysis were conducted for data analysis. Arithmetic mean (X) and standard deviation (sd), minimum (Min) and maximum (Max) value of the data were found and significance level was accepted as p<0.05.

3 | RESULTS

In measurements obtained from all CT images, average AD was found as 59.92 ± 4.71 mm, while average Depth was found as 18.69 ± 2.43 mm.

Measurement results showed that AD was 61.38 ± 3.41 mm in males, while it was 58.25 ± 2.72 mm in females. Average depth was 19.01 ± 2.84 mm in males, while it was 18.27 ± 1.74 mm in females. Mann-Whitney U test was conducted to find out whether there were statistical differences between

males and females whose AD and Depth measurements were conducted over CT images. According to the results of Mann-Whitney U test, statistically significant difference was found between males and females in terms of AD (p<0.05), while no differences were found in terms of Depth (p>0.05), (Table 1).

Parameter	Male			Female			p
	X ± sd	Min	Max	X ± sd	Min	Max	
AD	61.38 ± 3.41	52	70.5	58.25 ± 2.72	53.5	62.1	.000
Depth	19.01 ± 2.84	14	23.4	18.27 ± 1.74	13.1	22.5	.106

Table No.1 - Results of AD and Depth obtained from CT images of men and women

Correlation analysis was conducted on to find out how AD and Depth differed in males and females included in the radiological study in terms of age. Correlation analysis results did not show a statistically significant correlation between AD and Depth (p>0.05). A positive significant correlation was found between AD and Depth in males and females (p<0.05),

4 | DISCUSSION

Prosthetists and biomechanical engineers use anatomical parameters of hip joint while designing the best possible population specific prosthesis for hip replacement surgery. The complications caused by the mismatch of the prosthesis in total hip replacement surgeries can be prevented this way. Many prosthetists were found to design prosthesis by considering the parameters available from Western countries. On the contrary, this study will present parameters characteristic of Turkish population and help prosthetists to design much better prosthesis.

Aktas, et al. reported that the morphometry of the hip joint displayed ethnical differences (13). They measured the acetabular depth in various age groups and found depths between 10.00 and 11.1 mm. Arsic, et al. found difference between males and females in terms of depth in their study they conducted on CT images (14). In this study, we found statistically significant difference between AD measurements between males and females.

In their radiological study, Park and Im, found Depth as

11.8 ± 2.9 mm in males whose average of age was 47.5 ± 17.5 mm and as 11.4 ± 2.5 mm in females whose average of age was 55.6 ± 18.5 mm (15). Devi and Philip found Depth values between 21.8 mm and 34.6 mm and the average as 28.32 ± 1.32 mm (10), Tastekin Aksu, et al. found Depth values between 22.6 mm and 38.6 mm and the average as 29.49 ± 4.2 mm (6), Parmara, et al. found Depth values between 19.07 mm and 32.13 mm and the average as 29.49 ± 4.2 mm (16). Although the Depth results of this study do not completely match with the results of the above mentioned studies, they are similar. Devi and Philip found AD values between 42.8 mm and 61.5 mm and the average as 50.99 ± 1.99 mm (10), Tastekin Aksu, et al. found AD values between 44.8 mm and 65.5 mm and the average as 54.29 ± 3.8 mm (6), Parmara, et al. found AD values between 42.54 mm and 56.60 mm and the average as 42.54 ± 3.6 mm (16). The AD results in this study were found to be similar to those in aforementioned studies. Tastekin Aksu, et al. found positive significant correlation between AD and Depth (6). This result is in parallel with the results of our study. In their study they conducted on Chinese population, Zeng, et al. did not find any correlations between AD and Depth in females with an average age of 44.2 ± 5.27 and in males with an average age of 48.2 ± 8.47 mm (17). This result is not in parallel with the results of our study. Many authors like Croft, et al. Lau, et al. Smith, et al. Lane, et al. and Lequesne, et al. studied AD on CTs. As a result their studies show much lower values as compared to present study values (18).

5 | CONCLUSION

We believe that the differences between the results of our study and other studies are related with environmental and ethnic factors. Other studies on this subject will clarify the subject. Knowing the morphology of acetabulum morphology is a prerequisite to understand the mechanism of hip joint. We believe that the results of our study will contribute to studies about hip arthroplasty applications. In addition, we believe that a data base will be formed about this subject related with our region.

Acknowledgements - We would like to thank all the participants of this study **for their Support**.

6 | FUNDING: NO FUNDING SOURCES.

Conflict of interest: None declared ,

Consent – Yes

REFERENCES

1. Menschik F. The hip joint as a conchoid shape. *J Biomech.* 1997;30(9):971–973.
2. Standring S. Elsevier Churchill Livingstone; 2005.
3. Denham RA, Alexander LW. Arthroplasty of the hip. *J Bone Joint Surg.* 1957;39:614–622.
4. Arıncı K, Elhan A. *Anatomi (I. Cilt). Ossa Membri Inferioris-Acetabulum.* Ankara: Güneş Kitabevi. 2006;p. 19–19.
5. Ergun M, Hayran M. *Anatomi. N A, editor Alt Ekstemite Kemikleri Ankara: MN Medikal Nobel Tıp Kitabevi, editors; 2014.*
6. Aksu T, F, Çeri G, Arman N, Tetik C, S. Morphology And Morphometry of The Acetabulum. *DEÜ Tıp Fakültesi Dergisi.* 2006;20(3):143–148.
7. Javadekar BS. A study of measurements of femur with special reference to sex. *Journal of Anatomical Society of India.* 1961;10:25–27.
8. Govsa F, Ozer MA, Ozgur Z. Morphological features of the acetabulum. *Arch Orthop Trauma Surg.* 2005;125:453–461.
9. Dhindsa GS, Singh P, Singh Z. Acetabulum: a morphometric study. *J Evol Med Dental Sci.* 2013;5(2):659–665.
10. Devi TB, Philip C. Acetabulum-Morphological and Morphometrical Study *RJPBCS.* 2014;5(6):793–799.

AN ANALYTICAL STUDY OF DIAMETER AND DEPTH MORPHOMETRY IN HUMAN ACETABULUM

11. Murray RO. The etiology of primary osteoarthritis of the hip. *Br J Radiol.* 1965;38(455):810–824.
12. Benazzi S, Maestri C, Parisini S, Vecchi F, Gruppioni G. Sex assessment from the acetabular rim by means of image analysis. *Forensic Sci Int.* 2008;180(1):58–59.
13. Aktas S, Pekindil G, Ercan S, Pekindil Y. Acetabular dysplasia in normal Turkish adults. *Bull Hosp Jt Dis.* 2000;59(3):158–162.
14. Arsić S, Ilić D, Mitković M, Tufegdžić M, Janković S; 2013.
15. Park JM, Im G. The Correlations of the Radiological Parameters of Hip Dysplasia and Proximal Femoral Deformity in Clinically Normal Hips of a Korean Population. *Clin Orthop Surg.* 2011;3(2):121–127.
16. Parmara G, Rupareliab S, Patelc SV, Patelb SM, Jethvaa N. Morphology and Morphometry of Acetabulum. *Int J Biol Med Res.* 2013;4(1):2924–2926.
17. Zeng Y, Wang Y, Zhu Z, Tang T, Dai K. Differences in acetabular morphology related to side and sex in a Chinese population. *J Anat.* 2012;220(3):256–262.
18. Croft P, Cooper C, Wickham C, Coggon D. Osteoarthritis of the hip and acetabular dysplasia. *Annals of the Rheumatic Diseases.* 1991;50:308–310.

How to cite this article: Khare D.S., Kanwar D.Y. **An analytical Study of Diameter and Depth Morphometry in Human Acetabulum.** *Innovative Journal of Medical and Health Science.* 2020;897–900. <https://10.15520/ijmhs.v10i04.2859>