

EFFECTIVENESS OF GLYCYRRHIZINIC ACID AND AN IMMUNOSTIMULANT TO TREAT GENITAL WARTS IN THE PEDIATRIC PATIENT POPULATION

Edelisa Moredo Romo, Fernanda Pastrana Fundora, César R. Ramírez Albajés, Yelenin Rodríguez Porres, **Zelenkova Hana**

Hospital Pediátrico Docente Juan Manuel Márquez, Havana (Cuba), Private Clinic of Dermatovenerology, Svidni Slovakia.

ARTICLE INFO

Corresponding Author:

Hana Zelenkova, M.D., Ph.D.
Privat: Hrabova 735/10
089 01 Svidnik, Slovakia

Keywords: Anogenital warts, Viusid, Glizygen, glycyrrhizinic acid, immunomodulator, HPV infection

ABSTRACT

Background: Anogenital warts are proliferations of skin and mucosa caused by the Human Papilloma Virus (HPV) infection which is becoming increasingly more common among the pediatric patient population. **Objective:** Evaluate the effectiveness of combining glycyrrhizinic acid (Glizigen) with a food supplement (VIUSID) to boost the immune system when treating external anogenital warts in pediatric patients. **Method:** A longitudinal, randomized, double-blind, controlled, phase IV clinical trial was carried out on 76 patients of both genders aged between 6 and 18, who had been diagnosed with anogenital warts. The treatment consisted in the topical application of glycyrrhizinic acid together with the food supplement that was taken orally, three times a day for twelve weeks, with fortnightly check-ups, to evaluate the effectiveness of this combination according to the patient's response to the treatment and to identify any adverse reactions experienced. The relationship between the time taken for the lesions to disappear and the patient's response to the treatment along with the reduction in the number of lesions and their clinical presentation were all taken into account. **Results:** The lesions of 68.4% of the patients (26 individuals) disappeared altogether and for the other 28.9% (11 patients) the lesions decreased by more than 75%. Out of the 26 patients whose lesions disappeared completely, this happened in the first 4 weeks for 61.5% and between the 5th and the 8th week for the other 38.5%. The papillomatous lesions responded better to the treatment and no adverse reactions were observed during the clinical trial. **Conclusion:** The combination of glycyrrhizinic acid and the immunostimulant food supplement is a safe and effective alternative to treat anogenital warts affecting the pediatric patient population.

©2013, IJMHS, All Right Reserved

INTRODUCTION

Warts are caused by a virus, in particular, by the Human Papilloma Virus (HPV). These HPV are non-enveloped, double-stranded DNA viruses which have icosahedra symmetry with a capsid composed of 72 capsomers that belong to the **Papovaviridae** family. As a rule, they infect the epithelial cells, where they grow slowly and reproduce inside the nucleus of the host cell.⁽¹⁻³⁾

Normally, the HPV are divided in cutaneous and mucosal. Cutaneous HPV (types 1, 2 and 4) cause common and plantar warts. Around 40 of over 120 types of papillomavirus that have been molecularly identified are sexually transmitted and can infect the genital mucosa.^(4,3)

External genital warts (GW) are papillary excrescences and circumscribed hyperkeratotic lesions that vary in size and colour and they can have different clinical signs and symptoms.

The incubation time of the condyloma acuminata (CA) is anywhere from 3 weeks to 8 months, although the average time is 2 to 3 months. The most contagious stage is at 6 months because this is when the concentration of virus particles is at its highest. 33% of the lesions might disappear on their own due to spontaneous remission; it just depends on the host's immune response. The CA is one of the most common sexually transmitted diseases among sexually active young people and adults. Nowadays, the human papillomavirus infection is a social-health problem that is affecting an increasingly younger population; 600 million individuals are thought to be infected and 190 million with clinical infection.⁽⁴⁾ There aren't any official statistics on the prevalence of the HPV infection in Latin America.⁽⁵⁾ In Cuba, 83,521 cases were reported in the period 1990-2003.⁽⁶⁾

HPV is primarily transmitted through contact (sexual, an open wound coming into contact with contaminated material, contact with surfaces that are infected with the virus), and occasionally, vertical transmission (diaplacental) or perinatal (contact with the birth canal).

Genital warts are benign proliferations of skin and mucosa caused by the Human Papilloma Virus infection; they can be located on the penis, vulva, scrotum, perineum and the perianal area; the cervix, urethra, anus, mouth, and also in the conjunctiva, the nose and the larynx. They vary in appearance; some are pinpoint papules, others are cauliflower-like masses. They can be red, pink or skin colour. Depending on the size and the anatomical location, they can be painful, friable or itchy. Even though they are usually asymptomatic, they do have a considerable psychological impact on the sufferer.⁽⁵⁾

HPV is one of the most common sexually transmitted diseases in the world, so much so that virtually every single individual who is sexually active will be exposed to this virus at some stage in their lives. Nowadays, the HPV genital infection is known to have an important role in the genesis of pre-neoplastic lesions.^(7,8)

For centuries what has been discovered about this disease has been documented. According to their different genome homology, these viruses are subdivided into types, subtypes and groups. So far, more than 60 different types have been isolated and there are 35 types that can affect the genital areas. Some are potentially oncogenic alone or when combined with other carcinogenic factors.

Many products have been used to treat anogenital warts. There is now a huge variety of treatment including: 0.5% Podofilox either in solution or gel. When this is applied, the majority of patients experience itching or mild to moderate pain in the affected area, which is not however a reason to stop the treatment.⁽⁹⁾ 5% Imiquimod cream is an immunostimulant that can be administered by the patients themselves. Local inflammation is often reported after using this cream, although it is usually just mild or moderate.^(10,11)

Cryotherapy with liquid nitrogen destroys the lesions by means of a thermal-induced cytolysis system. Pain is often experienced after liquid nitrogen has been applied, which is followed by necrosis and sometimes a blister forms.⁽¹²⁾

80-90% trichloroacetic acid or bichloroacetic acid are very powerful keratolytic agents that can get through the stratum corneum quite easily and cauterize the skin, although this isn't usually enough to kill off the wart virus and often they reappear. There is no proof yet that they are harmless during pregnancy (category C). Although these preparations are often used, they have not been studied in great detail.⁽¹³⁾

Surgery is considered to be especially beneficial for patients with many lesions and/or lesions that affect a large area of the body, and those suffering from intraurethral warts, especially for patients that do not respond well to other types of treatment. Another possible surgical procedure that has proved to be effective is the resection of warts using CO₂ laser.⁽¹³⁾

Other medicine such as intralesional interferon, 25% podophyllin and allium sativum⁽¹⁴⁾, bleomycin and 5-fluorouraci⁽¹⁵⁾, or laser therapy are all reported to work on anogenital warts to a certain degree.

Recently, chemopuncture with vitamin B12 was tested out on a group of patients in our country and the results of this were very encouraging.⁽¹⁷⁾

Although there is wide variety of products available nowadays to treat external anogenital warts, their success rate tends to vary quite a lot and usually they only manage to destroy part of the lesions, but they don't seem to modify the progression of the disease. Furthermore, the majority of them are painful when applied and they can permanently scar the affected area.

In view of the aforementioned, it was decided that a user-friendly, non-invasive type of therapy, with minimum side effects should be used to treat the anogenital warts affecting children, for a relatively short period of time to control or get rid of the lesions permanently.

The therapy in question is a natural product that is extracted directly, by means of a Molecular Activation process, from liquorice root (*Glycyrrhiza glabra*), which is a very popular medicinal plant. It is very well-known for its anti-inflammatory and antiviral properties; it is also a demulcent, germicide and an antibacterial agent. The main active ingredient (glycyrrhizinic acid 0.1 g in 100 mg of the vehicle) interacts with viral proteins and according to the stage of the viral infection it can result in: The inactivation of extracellular free virus particles, the prevention of the intracellular decapsulation of infectious particles, and the deterioration of the assembling capacity of the structural components of the virus.

Its beneficial effects are enhanced by a Molecular Activation process that considerably improves the biological activity of the antioxidant molecules and all those that contain carboxyl groups in their structure; it can also make antiviral activity up to 10,000 times as effective.

For our study, this product was combined with a food supplement that enhances its effect; among other things, it contains glycyrrhizinic acid and its known for its role in the production of gamma interferon, reducing the tumour necrosis factor and the secretion interleukin 1 (IL-1) in turn, it stimulates the IL-10.

The treatment has had good results when it has been used to treat warts in adults, which is why it was decided that it should also be used on patients with anogenital warts that were being treated at the Dermatology unit at the Hospital Pediátrico Docente Juan Manuel Márquez in Havana from 2010-2011, given that it is a user-friendly, cosmetically acceptable product.

Objectives

The objective of our study was to evaluate the effectiveness of combining glycyrrhizinic acid (GA) and a food supplement to boost the immune system when treating external anogenital warts in the pediatric patient population and determine any adverse reactions that might be experienced due to the treatment, which is a user-friendly, effective combination with very few risks for the aforesaid patients.

Method

A longitudinal, randomized, double-blind, controlled, phase IV clinical trial was carried out on patients of both genders and all skin colours, aged between 6 and 18, who had been diagnosed with anogenital warts. They had not suffered from any immunodeficiency disorders or other sexually transmitted diseases in the past (syphilis, HBsAg, HCV and HIV-negative). They were being treated at the Dermatology unit of the Hospital pediátrico

Hana et.al/ Effectiveness of glycyrrhizinic acid and an immunostimulant to treat genital warts in the pediatric patient population

Docente Juan Manuel Márquez in Havana. Both groups (A and B) were made up of 38 patients, for a total sample of 76 cases that were photographed before and after the treatment; all the patients had to sign an informed consent document. (fig. 1)

The non-parametric statistical method was used along with the chi-square test of independence or homogeneity, whereby a type 1 error was accepted for the hypothesis testing to make sure that our results were 99% reliable.

Main variables

- **Fewer lesions at the end of the treatment**

Excellent: 100% of the lesions had disappeared at the end of the treatment.

Good: The lesions had decreased by between 75% and 100%.

Normal: The lesions had decreased by between 50% and 75%.

Bad: Less than 50% or the clinical condition was the same as in the beginning.

Secondary variables

- **Time taken for the lesions to disappear**

Excellent (E) The lesions disappear in 1 to 4 weeks of treatment.

Good (G) The lesions disappear in 5 to 8 weeks.

Normal (N) The lesions disappear in 9 to 12 weeks.

Bad (B) The lesions are still there after 12 weeks of treatment or the clinical condition got worse.

- **Adverse effects were observed while the treatment was being administered**

Null (N) No adverse effects were experienced.

Mild (mi) The adverse effect does not interfere in any significant way with the subject's daily activities; it might cause transient discomfort, or an adverse event that does not require treatment.

Moderate (M) The adverse effect does limit or interfere with the subject's daily activities, but does not put their health at risk; it may require treatment but after this it goes away.

Quite severe (QS) The adverse effect significantly limits the subject's daily activities or their organism although it is not life-threatening; its clinical significance might be irrelevant, but it lasts quite a time, or the subject suffers from a very severe case of such and does not respond to the treatment administered or they might have to temporarily stop using the product that is being tested.

Severe (S) When the product being used is life-threatening.

Method of use of the treatment

All the patients' lesions were counted and their appearance was recorded (flat or papillomatous lesions), they were randomly assigned the product by the head of the clinical trial. The identity of those in groups A (those who were given the medicine) and those in group B (those who were given the placebo) was only revealed at the end of the study.

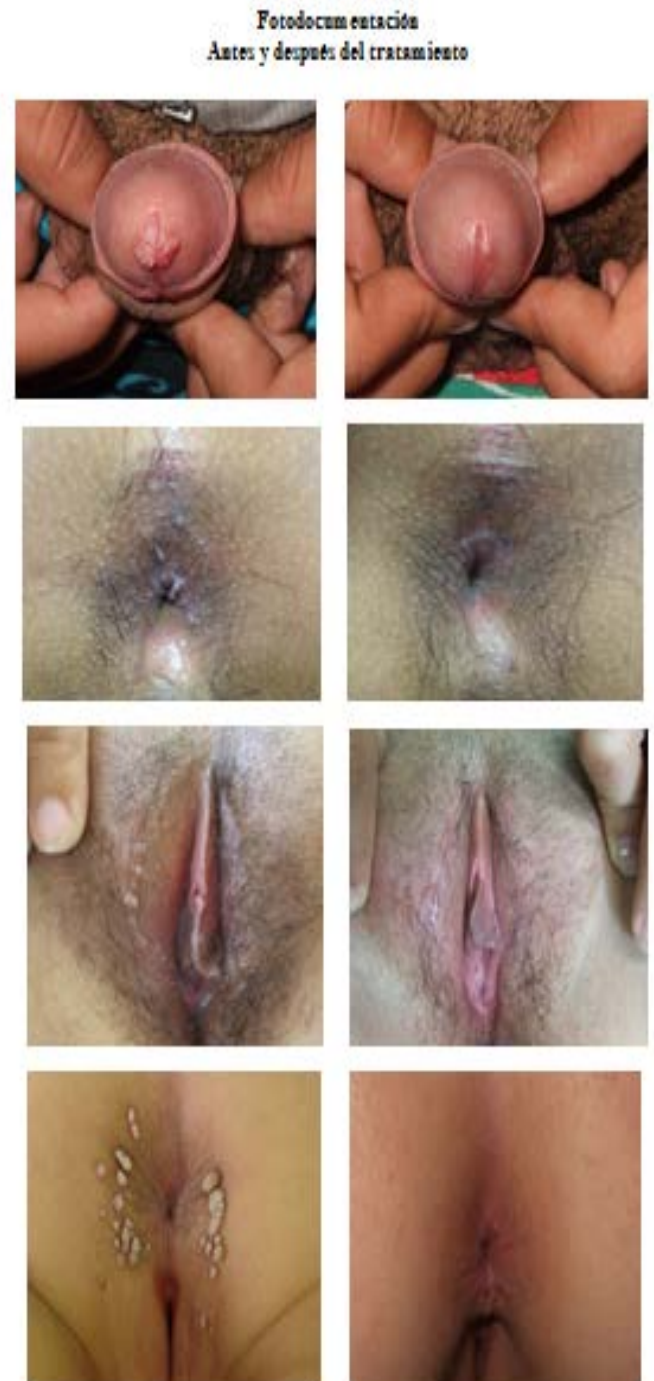The topical Glycyrrhizinic Acid was sprayed on the affected area 3 times a day and 1 sachet containing 4 g of the food supplement was taken orally (patients aged from 6-12 were given 2 sachets a day and those aged 13-18 were given 3 sachets a day, according to the criteria established by the product manufacturers). The patients were assessed every fortnight at the unit to see how they were progressing. If after the eighth week of treatment there was no change in the lesions, a change to a more conventional

type of therapy or the combination of the product with another were considered.

All the patients from the treatment group completed the clinical trial, whilst 6 patients from the group that were given placebo had to abandon it.

The decrease in the number of lesions, the time taken for them to disappear, their clinical presentation and any adverse events experienced were all taken into consideration when evaluating the results.

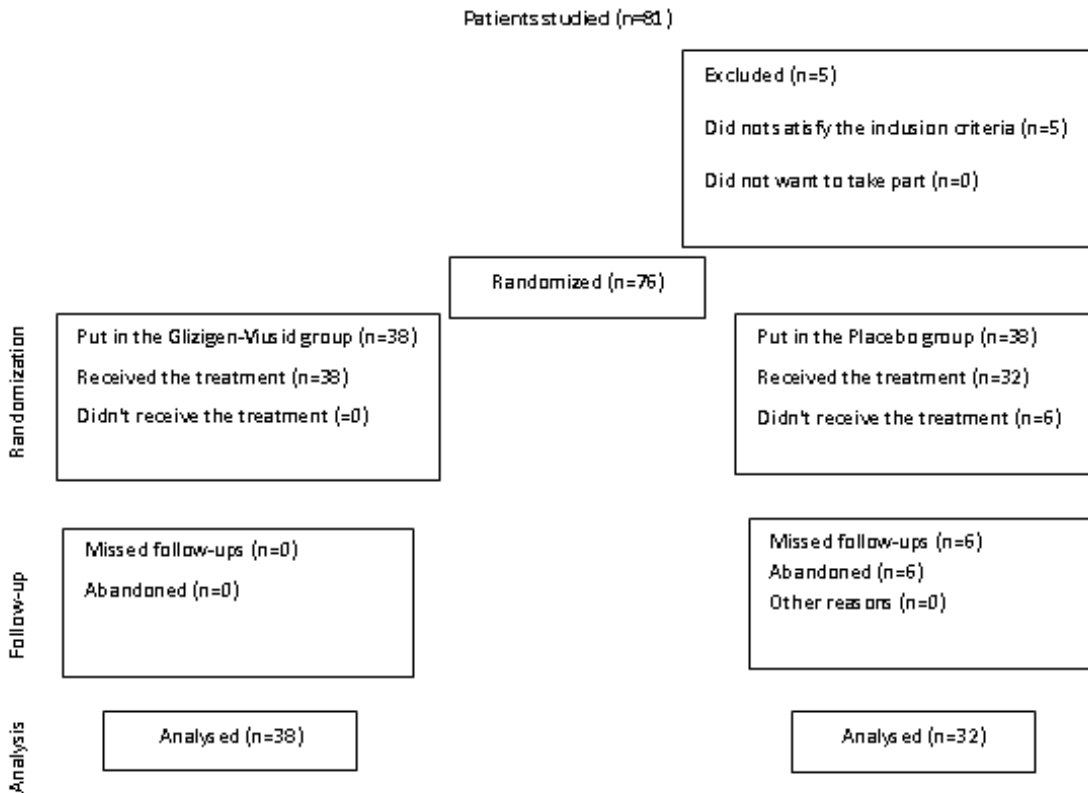
Fig. 1 Photodocumentation Before and after the treatment



RESULTS

All in all, 76 patients were included in the clinical trial, 38 of them (Group A) were given medicine and 38 (group B) were given placebo, 6 patients from Group B left the clinical trial on their own free will. (Fig. 2)

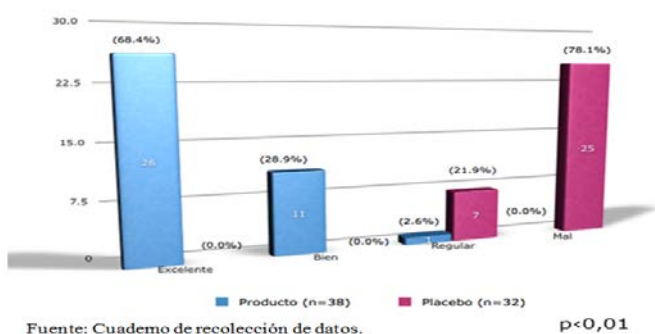
Figure 2. Flow chart of



Out of the 76 patients included in the clinical trial, 80.3% of them were male and the other 19.7% were female; the infection was seen to affect those aged between 15 and 18 the most.

On analysing the response at the end of the treatment according to the decrease in the number of lesions, in the group that was given the medicine (group A for N=38), the lesions disappeared in 26 cases, that is, 68.4% of the patients, which was considered to be an excellent result. Then in 11 cases, 28.9% of the patients, the lesions decreased by more than 75%, which was considered to be a good response. Only 2.6% of the patients had a normal response because their lesions only decreased by 50%. In the group that was given placebo (group B for N=38), 6 patients abandoned the clinical trial because they were not responding to the treatment, the progress of 25 patients (65.8%) was considered to be bad because their lesions either stayed the same or they got worse and the lesions in 7 patients (18.4%) decreased by less than 50%. (Graph 1)

Gráfico 1. Relación entre la respuesta al tratamiento y la reducción del número de Lesiones



Graph 1. Relationship between the response to the treatment and the decrease in lesions

As for the time taken for the lesions to disappear, we found that for the 26 patients whose lesions disappeared altogether, this occurred in the first 4 weeks of treatment for 16 of them, that is 61.5%. For the other 10 patients (38.5%) it took between five and eight weeks of treatment. None of the patients from group B managed to get rid of their lesions completely. (Table 1)

Table 1. Relationship between the time taken for the lesions to disappear and the response to the treatment in 26 patients who managed to get rid of all the lesions.

Time taken for the lesions to disappear	Patients with medicine N=26	
	No.	%
Excellent (The lesions disappear in the first 4 weeks of treatment)	16	61,5
Good (The lesions disappear in the first 5 to 8 weeks of treatment)	10	38,5
Normal (The lesions disappear in the first 9 to 12 weeks of treatment)	-	-
Bad (The clinical condition stays the same or gets worse)	0	0
Total	26	100.0

Source: Data collection record (p<0.01)

On studying the appearance of the lesions, the papillomatous warts seemed to respond faster to the treatment than the flat warts. No adverse reactions were observed in either group during the clinical trial.

DISCUSSION

Becoming sexually active earlier on in life plus the frequent change in sexual partners could be the reason why there is an increase in anogenital warts suffered by the adolescents in our study, in which the majority of patients were aged between 15 and 18. In the literature review, no

studies were found to provide us with a casuistry that could be compared with our own work.

The majority of the treatment used nowadays has to be administered by health care providers or a paramedic as it involves the physical destruction of the infected cells; however none of these are consistently effective nor can they be thought of as being directly antiviral.

With the combination of Glycyrrhizinic Acid (natural substance, commonly known as "sweet root", that was used way back in ancient Egypt and China) and an immunostimulant that enhances the action of this product, we have been able to get excellent results in terms of reducing the number of lesions and even get rid of them altogether; this was the case of 97.36% of the patients treated (excellent and good responses). They managed to completely cure the affected areas by the end of the clinical trial or reduce their lesions by more than 75%, thanks to a user-friendly, practically harmless method.

Other authors have obtained very similar results when this product has been used on HPV infections.^(17, 18, 19)

It is very important to point out that an improvement in the clinical condition of 100% of the patients was observed, so if the treatment is administered for even longer, it might get rid of all the lesions permanently.

7 of the patients who were given placebo had a normal response, their lesions decreased by less than 50%. This might be associated with the individual's own immunocompetence, given the fact that it is a viral infection.

In our clinical trial, the lesions of 16 patients (61.5%) out of 26 cases cleared up completely, all their lesions disappeared in the first four weeks of the treatment; very similar results were obtained in the study carried out by Dr. Zelenkova⁽¹⁸⁾; moreover the lesions of the remaining 38.5% cleared up before the eighth week.

The results of the treatment, regardless of whether the lesions were flat or papillomatous, were classified as being satisfactory because the majority of the patients had positive results. However the papillomatous lesions were seen to progress better than the flat lesions. The literature review makes no reference to the relationship between the appearance of the lesions and the response to the treatment, although this might be related to the specific type of virus that affects a certain patient.

None of the patients had any symptoms that could have been associated with adverse reactions to the treatment used. Indeed with this combination of treatment, even though the response is not immediate as in the case of electrofulguration, cryosurgery, etc., it is more popular among the paediatric patient population and their parents or guardians, because it's not painful, they can use it themselves, there's never or hardly ever any adverse reactions and there are no sequelae or psychological trauma which might affect the younger patients in particular. This all corroborates the criteria established by other authors that believe that using GA is effective in treating external anogenital warts^(17, 18, 19, 20) and that this effect is enhanced when it is combined with an immunostimulator.

CONCLUSIONS

Using glycyrrhizinic acid combined with an immunostimulant food supplement did prove to be effective in treating the external anogenital warts in the

pediatric patient population and harmless, which is why we think that this type of therapy should be used at other centres in order to give our patients higher quality and more effective care.

BIBLIOGRAPHY

1. Munoz N, Bosch FX, de Sanjose S, Herrero R, Castellsague X, Shah KV, et al. Epidemiologic classification of human papillomavirus types associated with cervical cancer. *N Engl J Med* 2003; 348(6):518-27.
2. Shew ML, Fortenberry JD. PVH infection in adolescents: natural history, complications, and indicators for viral typing. *Semin Pediatr Infect Dis* 2005;16(3):168-74
3. Trottier H, Franco EL. The epidemiology of genital human papillomavirus infection. *Vaccine* 2006; 24 Suppl 1:S1-15.
4. Menéndez M, Hernández M. Actualización de la terapéutica del papilomavirus humano. *Terapia convencional. Rev Cub Med*, 2004:43
5. Obanza Wincheids, EF, González AL. Condiloma Acuminado. *Guías Clínicas en Atención primaria* 2003; 3 (33). Disponible on-line en <http://www.fisterra.com.br/>
6. Dirección Nacional de Estadísticas. MINSAP. Cuba, 2004.
7. Winer RL, Lee SK, Hughes JP, Adam DE, Kiviat NB, Koutsky LA. Genital human papillomavirus infection: incidence and risk factors in a cohort of female university students. *Am J Epidemiol* 2003; 157: 218- 26.
8. Collins S, Mazloomzadeh S, Winter H, Blomfield P, Bailey A, Young LS, et al. High incidence of cervical human papillomavirus infection in women during their first sexual relationship. *Bjog* 2002; 109(1):96-8.
9. Kirby P, Dunne A, King DH, Corey L. Sexually transmitted diseases treatment guidelines. 2002.
10. Asociación Americana de la Salud Social; 2009. Disponible en: <http://www.ashatd.org>; Visitado el 30 de noviembre del 2010.
11. *Actas Urol Esp* v.31 n.3 Madrid mar. 2007
12. Andrews G, Domonkos A. Enfermedades víricas en: *Tratado de Dermatología*. 5ta Ed., Editorial Médica Panamericana. p. 486. 2004
13. Bourgault Villada I. Infecciones vulvares et périnéales induites part HPV: quels traitements? *Réalités thérapeutiques en dermato-vénérpologie*. No. 201; 2010: 22-26
14. Pérez Armas R. Eficacia terapéutica comparativa entre d la podofilina al 25% y el allium sativum en los condilomas acuminados. *Rev. Cienc méd. (9) Supl. 5, Ciudad Habana*. Dic.2010.
15. Sergio Batista C. 5-Fluorouracil tópico para tratamiento do condiloma genital em pacientes não imunocomprometidos. [Resumen de Tesis]. *Rev. Bras. Ginecol. Obstet.* Rio de Janeiro 2010; vol.32 (7)
16. Miranda Díaz BT. La quimiopuntura, nueva estrategia de tratamiento del paciente con condiloma acuminado recidivante. *Rev. Med. Electrón. [revista on line]*. 2009 Ago [citado 2011 Mayo 09] ; 31(4): Disponible en: http://scielo.sld.cu/scielo.php?script=sci_arttext&pid=S1684-18242009000400008&lng=es
17. Gómez Domínguez J, Daniel Simón R, Abreu Daniel A. Eficacia del Ácido Glicirricínico (Glizigen) y un

Hana et.al/ Effectiveness of glycyrrhizinic acid and an immunostimulant to treat genital warts in the pediatric patient population

inmunoestimulador (Viusid) en el tratamiento de Verrugas Genitales. Folia dermatológica cubana [Revista on line].2008 Sept-Dic. [citada 12 de noviembre del 2010];2(3): Disponible en: <http://bvs.sld.cu/revistas/fdc/indice.html>

18. Zelenková, Hana; Nejdková, Alena; Škutilová, Eva; Urbáni, Milan; Švecová, Danka; Cabalová, Jirina. Preparations containing Glycyrrhizic Acid in dermatological Practice. First results of the international multicentre study.2007
19. Espinoza, Angel; Barragán, Luis. Estudio longitudinal, prospectivo, abierto, sobre la evaluación de la efectividad, la seguridad clínica y la tolerabilidad local de la administración repetitiva (q.id.) por 10 días del ácido glicirricínico activado (Epigén) en pulverizaciones locales a pacientes cursando con infección por virus del papiloma humano (HPV) a nivel del cérvix uterino. Clínica de Detección y Tratamiento de Displasias, Universidad de Guadalajara, México. Noviembre 2004
20. Mungía MA. Eficacia del ácido glicirricínico activado, con relación al nitrógeno líquido, y a la combinación de ambos, en el tratamiento del condiloma acuminado en pacientes atendidos en el Centro Nacional de Dermatología [Tesis de Especialista]. UNIVERSIDAD NACIONAL AUTÓNOMA DE NICARAGUA. UNAN-MANAGUA.; 2006.