

DEALING DUAL FRACTURE WITH DUAL CURE RESIN - A CASE REPORT

Utpal Kumar Das¹ Aditya Mitra, Nabanita Bose

Department of Conservative Dentistry & Endodontics, Guru Nanak institute of Dental Science and Research, Kolkata, India

ARTICLE INFO

Corresponding Author:

Dr. Nabanita Bose
BDS, Department of Conservative
Dentistry & Endodontics, Guru
Nanak institute of Dental Science
and Research, Kolkata, India.

Key words: Dental Trauma,
Fiber Post, Dual Fracture,
Fragment Reattachment.

ABSTRACT

Dental trauma often has a severe impact on the social and psychological well being of a patient. Traumatized anterior teeth require quick functional and esthetic repair. Traditionally such injuries have been restored with composite resins. They have the primary disadvantage of colour mismatch and variable wear. Therefore if a broken fragment is available, the restoration of the tooth using its own fragment has been suggested as an alternative. Reattachment of tooth fragment should be the first choice and is a viable alternative to conventional approaches because of simplicity, natural esthetics and conservation of tooth structure. Reattachment of fractured tooth fragments can provide good and long-lasting esthetics (because the tooth's original anatomic form, color, and surface texture are maintained. Patient cooperation and understanding of the limitations of the treatment is of utmost importance for good prognosis. The case report emphasis the innovative technique of managing both root fracture & coronal fracture treated successfully using tooth fragment reattachment. Agglutination of fractured parts to each other is performed using fiber post and dual cure resin is to preserve sound tooth structure and return loss tooth structure.

©2013, IJMHS, All Right Reserved

I. INTRODUCTION

Majority of dental injuries involves the anterior teeth, especially the maxillary incisors (because of its position in the arch), whereas the mandibular central incisors and the maxillary lateral incisors are less frequently involved. Dental injuries usually affect only a single tooth; however, certain trauma types such as automobile accidents and sports injuries involve multiple tooth injuries[1].

Management of dental injuries requires a comprehensive and accurate diagnostic and treatment plan [2]. Choosing a treatment approach for a complicated crown fracture depends on the level and position of tooth fracture line, availability of displaced tooth fragments, type of occlusion and prognosis [3,4]. A number of techniques have been reported for the treatment approach of fractured anterior teeth such as the use of the tooth fragment either as a temporary or permanent crown, definitive crown after an orthodontic and surgical extrusion or a crown lengthening, extraction followed by implant or fixed partial denture, composite restorations and post core supported restorations [5].

Reattachment of tooth fragments can be used only when the intact tooth fragment is available and this technique is a viable alternative to conventional approach with minimal or without violation of biologic width.[6,7]. Tooth fragment reattachment offers a conservative, esthetic, and cost effective restorative option that has been shown to be an acceptable alternative to the restoration of the fractured tooth with resin-based

composite or full-coverage crown.[8,9-11]. It can restore function and result in a positive psychological response, and is a reasonably simple procedure. [12]. Furthermore, this technique is less time-consuming and provides a more predictable long-term wear than when direct composite is used.[13]. Clinical trials and long-term follow-up have reported that reattachment using modern dentin bonding agents or adhesive luting systems may achieve functional and esthetic success.[8,14].

Several aspects may govern the choice of a reattachment technique. Studies have reported that the primary cause of fragment loss is new dental trauma or the nonphysiological use of the restored tooth.[8]. Therefore, most concerns about reattachment techniques have been directed toward the fracture strength of the restored tooth.[15,16].

Clinicians have employed an assortment of bevel designs, chamfers, dentinal and enamel grooves, and choices of resin composite materials and techniques for the reattachment of tooth fragments. Reis and colleagues[16] have shown that a simple reattachment with no further preparation of the fragment or tooth was able to restore only 37.1% of the intact tooth's fracture resistance, whereas a buccal chamfer recovered 60.6% of that fracture resistance; bonding with an overcontour and placement of an internal groove nearly restored the intact tooth fracture strength, recovering 97.2 and 90.5% of it, respectively.

II. CASE REPORT

ii.i. Chief Complaints

A 45 year old male patient was referred to the department of Conservative Dentistry and Endodontics with the chief complaint of fractured maxillary right lateral incisor following an injury in workplace.

ii.ii.Clinical and Radiographic Examination

Clinical and radiographic examination revealed an oblique crown-root fracture with grade I mobility. (Fig.no.1, 2), revealing dual fractures.

Upon examination, the treatment options were presented to the patient and to his legal guardian, including

- (1) no treatment,
- (2) post & core and crown,
- (3) crown buildup restoration with a resin based composite, and
- (4) reattachment of the tooth fragment.

After some deliberation about the advantages, disadvantages, prognosis, and cost of every treatment option, the patient opted to have the tooth fragment reattached.

It is important to note that the reattachment option was presented only after confirming that the fragment was in good condition and that it fit reasonably well on the fractured tooth.

III.CLINICAL PROCEDURE

1.Isolation was achieved using cheek retractor,cotton rolls and saliva ejector placed in position.

2.Acid etching was done on both the fragment and the tooth using 37% phosphoric acid for 15 seconds and thoroughly rinsed off. A bonding agent was applied to both the substrates and light cured for 15 seconds. A dual cure resin was used for filling the interfragmentary space and the fit was reverified. The excess was removed and the composite layer was polymerized from both the labial and palatal surface.

3.Splinting was done from maxillary one canine to other canine for stabilization.(Fig.no.3)

4.After administration of local anesthesia,single-visit root canal treatment for radicular portion of the tooth was performed.Working length determination was done and biomechanical preparation was performed.Then the canal was obturated with gutta percha and AH-Plus sealer and the entrance of the root canal was sealed with glass ionomer.(Fig.no.4)

5.Post space was prepared with the corresponding drill to receive a prefabricated glass fiber post [FRC Postec Plus,Ivoclar Vivadent].The prefabricated post was checked in the canal for adaptation and was confirmed using radiographs.

6. Both post space and fiber post was etched with 37% phosphoric acid for 15 seconds and thoroughly rinsed.Then bonding agent was applied to both the post space and the fiber post.

7.Finally,post cementation was done with dual cure resin [Multilink Speed, Ivoclar Vivadent, LOT R64472] and excess portion of the post was cut.(Fig.no.5)

8.Excess resin was then removed and the area was light cured.

9.After completion of the endodontic therapy,splint was removed and crown reduction was done.(Fig.no.6)

10. Impressions for both the arches was taken.

11. Trial was done and finally cementation of the crown was done.The colour of the final prosthesis was comparatively lighter than the adjacent tooth which was as a result of patient's request.(Fig.no. 7)

12.Occlusion was checked and post operative instructions to the patient was given to avoid loading of anterior teeth.

13.The patient was recalled after 6 months for follow up and it was observed that both endodontic and restorative treatments remained clinically acceptable for the entire time.(Fig.no.8)

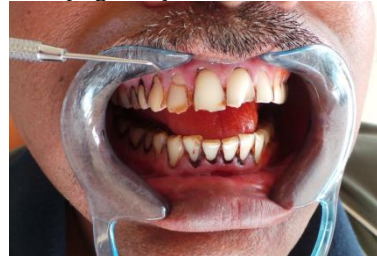

Fig.no. 1 Pre-operative view

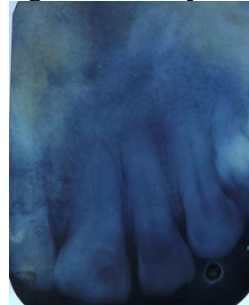

Fig.no. 2 Pre-operative IOPAR

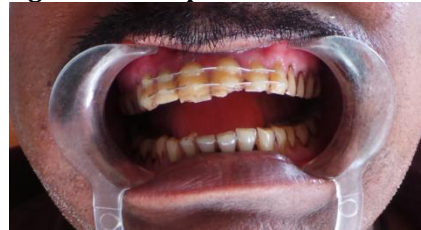

Fig.no. 3 Splinting



Fig.no. 4 Obturation

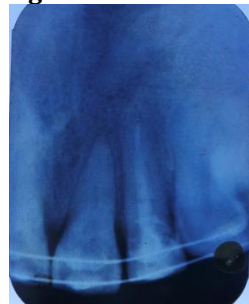


Fig.no.5 Cementation of fiber post with dual cure resin.

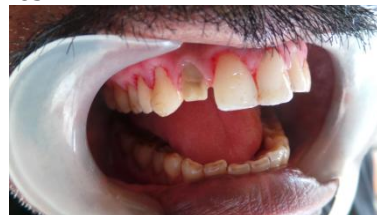

Fig.no.6 Crown reduction

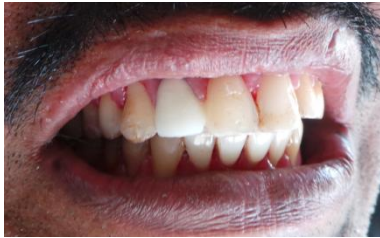

Fig.no.7 Cementation of crown

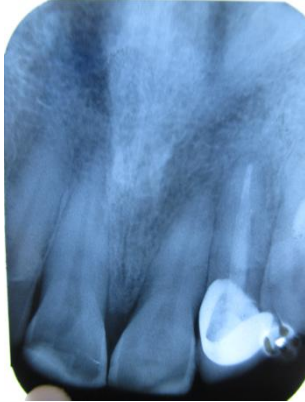


Fig.no.8 6 months follow up

IV.DISCUSSION

Protection of mechanical and functional integrity is one of the most important factors in the restoration of traumatized anterior teeth. There are many different treatment modalities for restoration of traumatized teeth such as composite resin restorations with and without pins and prosthetic repair [17]. Whenever the fractured fragment is available intact, the reattachment of the fragment has to be the most desired treatment.

Tooth fragment reattachment allows restoration of the tooth with minimal sacrifice of the remaining tooth structure. Improved esthetics is obtained since enamel's original shape, color, brightness and surface texture are maintained.

With advances in adhesive dentistry, the process of fragment reattachment has become simplified and more reliable [18].

Recently, different types of post materials have been introduced into the dental practice such as carbon fiber, quartz and glass fiber [19]. With the recent improvements in the dental materials resin based restorative materials with tooth coloured fiber post are of choice because of several advantages such as a suitable elastic modulus, esthetics, good bonding between post and cement, lower chair time and minimal tissue removal [20,21].

The use of a fiber post with fractured teeth, as it interlocks the two fragments, minimizes the stress on the reattached tooth fragment.

Esthetic, biologic and restorative problems may occur as a result of the fracture extending subgingivally and impinging on the biologic width. The treatment options depend on the relationship of the fracture to the alveolar crest, degree of pulpal involvement, amount of eruption, apex formation and esthetic requirement of the patient. Treatment alternatives include crown lengthening to restore the biologic width, flap surgery and osteotomy/osteoplasty to restore biologic width, followed by crown reattachment and rapid orthodontic extrusion possibly in conjunction with fiberotomy. [22].

V.CONCLUSION

Reports and clinical experience indicate that the reattachment of fractured coronal fragments results in successful short- and medium-term outcomes. [11,13,14].

Fabrication of a mouth guard and patient education about treatment limitations may enhance clinical success as reattachment failures may occur with new trauma or parafunctional habits.

Reattachment of a tooth fragment is a viable technique that restores function and esthetics with a very conservative approach. The fiber post system is an effective treatment option that provides regaining esthetic and functional completeness for the patient. Esthetic result can be obtained with a minimal number of procedures and cost to the patient.

However, the professional has to keep in mind that a dry and clean working field and the proper use of bonding protocol and materials is the key for achieving success in adhesive dentistry.

REFERENCES

- [1]. Andreasen JO, Andreasen F, Andersson L. Textbook and color atlas of traumatic injuries to the teeth. 3rd ed. St Louis (MO): Mosby; 1994.
- [2] Bruschi-Alonso RC, Alonso RC, Correr GM, Alves MC, Lewgoy HR, Sinhoreti MA, et al. Reattachment of anterior fractured teeth: Effect of materials and techniques on impact strength. *Dent Traumatol* 2010;26:315-22.
- [3] Aggarwal V, Logani A, Shah N. Complicated crown fractures-management and treatment options. *Int Endod J* 2009;42:740-53.
- [4] Villat C, Machtou P, Naulin-Ifi C. Multidisciplinary approach to the immediate esthetic repair and long-term treatment of an oblique crown-root fracture. *Dent Traumatol* 2004;20:56-60.
- [5] Meiers JC, Kazemi RB. Chairside replacement of posterior teeth using a prefabricated fiber-reinforced resin composite framework technique: A case report. *J Esthet Restor Dent* 2005;17:335-42.
- [6] Murchison DF, Burke FJ, Worthington RB. Incisal edge reattachment: indications for use and clinical technique. *Br Dent J* 1999;186:614-9.
- [7] Murchison DF, Worthington RB. Incisal edge reattachment: literature review and treatment perspectives. *Compend Contin Educ Dent* 1998;19:731-4,36,38 passim; quiz 44.
- [8]. Andreasen FM, Noren JG, Andreasen JO, et al. Long term survival of fragment bonding in the treatment of fractured crowns. *Quintessence Int* 1995;26:669-81.
- [9]. El-Askary FS, Ghalab OH, Eldemerdash FH et al. Reattachment of a severely traumatized maxillary central incisor, one-year clinical evaluation: a case report. *J Adhes Dent* 2006;8(5):343-9.
- [10]. Reis A, Loguercio AD, Kraul A, Matson E. Reattachment of fractured teeth: a review of literature regarding techniques and materials. *Oper Dent* 2004;29(2):226-33.
- [11]. Rappelli G, Massaccesi C, Putignano A. Clinical procedures for the immediate reattachment of a tooth fragment. *Dent Traumatol* 2002;18(5):281-4.
- [12]. Maia EA, Baratieri LN, de Andrada MA, et al. Tooth fragment reattachment: fundamentals of the technique and two case reports. *Quintessence Int* 2003;34(2):99-107.
- [13]. Baratieri LN, Monteiro S Jr., Andrada MAC. Tooth fracture reattachment: case reports. *Quintessence Int* 1990;21(4):261-70.

- [14]. Oz IA, Haytac MC, Toroglu MS. Multidisciplinary approach to the rehabilitation of a crown-root fracture with original fragment for immediate esthetics: a case report with 4-year follow-up. *Dent Traumatol* 2006;22(1):48-52.
- [15]. Farik B, Munksgaard EC, Andreasen JO. Impact strength of teeth restored by fragment-bonding. *Endod Dent Traumatol* 2000;16(4):151-3.
- [16]. Reis A, Francci C, Loguercio AD, et al. Re-attachment of anterior fractured teeth: fracture strength using different techniques. *Oper Dent* 2001;26(3):287-94
- [17]. Ozel E, Kazandag MK, Soyman M, Bayirli G. Two-year follow-up of fractured anterior teeth restored with direct composite resin: Report of three cases. *Dent Traumatol* 2008;24:589-92.
- [18] Wolcott J, Averbach RE. Management of complicated crown fractures: tooth fragment reattachment. *Compend Contin Educ Dent* 2002;23:520-4,26,28.
- [19] Asmussen E, Peutzfeldt A, Heitmann T. Stiffness, elastic limit and strength of newer types of endodontic posts. *J Dent* 1999;27:275-8.
- [20] Torabi K, Fattahi F. Fracture resistance of endodontically treated teeth restored by different FRC posts: an in vitro study. *Indian J Dent Res* 2009;20:282-7.
- [21] Akkayan B. An in vitro study evaluating the effect of ferrule length on fracture resistance of endodontically treated teeth restored with fiber-reinforced and zirconia dowel systems. *J Prosthet Dent* 2004;92:155-62.
- [22]. Richard D. Trushkowsky. Esthetic, Biologic and restorative considerations in coronal segment reattachment for a fractured tooth: a clinical report. *J Prosthet Dent*. 1998;79:115-119.