



ORIGINAL RESEARCH ARTICLE



Nuclear fractal dimensions - an indicator of nodal metastasis in Oral Squamous Cell Carcinoma

Kaorey Nivedita N^{1*} | Mandale Mandakini S² | Bhavthankar Jyoti D^{1,3} | Humbe Jayanti G⁴

¹Post-Graduate student

Department of Oral Pathology and Microbiology Government Dental College and Hospital, Aurangabad, India.

²Associate Professor Department of Oral Pathology and Microbiology Government Dental College and Hospital, Aurangabad, India.

³Professor and Head Department of Oral Pathology and Microbiology Government Dental College and Hospital, Aurangabad, India.

⁴Assistant Professor Department of Oral Pathology and Microbiology Government Dental College and Hospital, Aurangabad, India.

Abstract

Context: Cumulative appraisal of tumor size, lymph node involvement and metastasis is essential for evaluating the prognosis of any cancer. Oral cancer being no exception to this rule also shows lymph node metastasis in advanced stages. Oral cancer boasts of certain peculiar microscopic features, among which nuclear morphometric changes form a key component. Accuracy in identifying these nuclear changes will help in better prediction of the prognosis of oral cancer.

Fractal measurement is an offshoot of the computer aided image analysis which aids in the accurate analysis of the structural properties of histopathology specimens.

Aims: To evaluate the use of nuclear fractal dimensions (NFD) to predict lymph node metastasis in oral squamous cell carcinoma.

Settings and Design: A cross-sectional comparative study was carried out using archived histopathological tissue specimens of oral squamous cell carcinoma which were then subjected to morphometric analysis.

Methods and Material: 30 H&E stained sections of OSCC with and without lymph node metastasis were taken for the analysis. The microscopic images were captured from five representative high power fields from infiltrated dysplastic epithelial islands in the connective tissue and subjected to image analysis using Image Pro Premiere software. Well-stained, well-defined and non-overlapping neoplastic nuclei were semi-manually selected and subjected to fractal analysis.

Statistical analysis used: Statistical analysis was done by applying student's unpaired t-test and 'p' value below 0.005 was considered statistically significant.

Results: A mean Nuclear Fractal Dimension of 1.099 ± 0.0068 for OSCCs with nodal metastasis as opposed to NFD of 1.055 ± 0.0047 for OSCCs devoid of lymph node involvement was observed

Conclusions: Nuclear fractal dimensions may prove to be a valuable indicator in the assessment of prognosis oral squamous cell carcinoma.

Keywords: nuclear fractal dimensions, image analysis, nuclear morphometry

1 | KEY MESSAGES:

Exploring fractal dimensions of the nucleus of the neoplastic cells and correlating them with progression of oral squamous cell carcinomas in terms of nodal metastasis was undertaken successfully. A similar study with a larger sample size should be undertaken to reinforce the findings obtained in the current study

Cancers of the oral cavity have plagued the world for a long time and is one of the major causes of morbidity and mortality. Despite the advances in the treatment modalities the five years survival rate is still unsatisfactory. It has been reported that 40% of the cases of oral squamous cell carcinoma are associated with lymph node involvement among which 15-34% remain clinically undetectable. The five year survival rate of OSCC with lymph node metastasis is 21.54% whereas in cases without LN involvement it is 47.36%. [1] [2]

Thus it is apparent that an early and prompt diagnosis may aid in improving the prognosis of the oral cancers.

There are certain microscopic features which are peculiar to oral cancer, among which nuclear morphometric changes form a key component. Various facets of these nuclear changes have been adjudged using different methods such as conventional cytology and histopathology staining, special staining techniques, auto-fluorescence, image analysis etc. Of these, computer aided image analysis has emerged as a new adjunct in diagnosis and prognosis of various diseases including oral cancers.

Nuclear features form a crucial parameter in grading of oral squamous cell carcinoma (OSCC). Different nuclear morphometric parameters studied for epithelial tumours are nuclear area, nuclear perimeter, nuclear shape factor, ratio of smallest and longest axes (aspect ratio), nuclear size along with nuclear-cytoplasmic ratio and nucleolar- nuclear ratio [3]. Studies have been conducted in order to evaluate these parameters either individually or in combination to come up with the best possible predictor of the outcome of OSCC.

Benoit Mandelbrot in 1970 came forth with the concept of Fractal geometry. A ratio providing a statisti-

cal index of complexity by comparing how the detail in a fractal pattern changes with the scale at which it is measured is termed as a Fractal Dimension (FD) [4]. Fractal analysis has found applications in histopathology and cytology where it has been used for the estimation of the fractal dimensions of several neoplasms such as carcinomas of the gallbladder, lung, uterus, breast, larynx and oral cavity [5].

The current report is of a pilot study to assess the application of nuclear fractal analysis to determine nodal metastasis in oral cancers.

2 | AIMS AND OBJECTIVES

To measure the nuclear fractal dimensions in oral squamous cell carcinoma with and without regional lymph node metastasis. Along with comparison of the nuclear fractal dimensions between the two entities

3 | SUBJECTS AND METHODS

3.1 | Study population

This pilot study included archived, histologically proven cases of Oral squamous cell carcinoma with and without regional lymph node metastasis. The samples were segregated into two study groups -

Group N+ - OSCC with lymph node metastasis – 15 cases

Group N0 - OSCC without lymph node metastasis – 15 cases

Subjects with other systemic diseases and malignancies were excluded from this study.

Supplementary information The online version of this article (<https://doi.org/10.15520/ijmhs.v10i06.3014>) contains supplementary material, which is available to authorized users.

Corresponding Author: *Kaorey Nivedita N*
GDC Aurangabad
Email: niveditakaorey@gmail.com

Histopathological slides stained with H &E were prepared and examined for presence of features of OSCC. The histological images were then captured in 400x magnification with the help of Micropublisher 3.3 RTV. Fifty nuclei per field from five representative high power fields of each slide were analysed. These images were then subjected to analysis by using the image analysis software (Image Pro Premier) and subsequent calculation of the nuclear fractal dimensions were carried out.

Algorithm for analysis of fractal dimensions Figure 1 :

- Selecting image and standardizing image analysis
- Applying image red mode to eliminate colours other than white and black.
- Selecting an area of interest
- Creating new image and extracting the background image
- Adjusting the threshold histogram to obtain distinct, non-overlapping nuclei
- Extracting the nuclei & calculating the fractal dimensions for each nucleus using free hand cursor.

A single fractal value was calculated for each nucleus and an average fractal dimension for each slide was derived. Thus the FD for each case was tabulated and subjected to statistical analysis using the student's unpaired t-test

4 | RESULTS

Total average fractal dimensions of group N+ = 1.099 ± 0.0068

Total average fractal dimensions of group N0 = 1.055 ± 0.0047

The average fractal dimension of the nucleus was higher in cases of OSCC with lymph node metastasis as opposed to cases without nodal involvement. Statistical analysis was done by applying student's unpaired t-test and the 'p' value obtained was 0.0001 which was suggestive of a statistically significant difference Figure 2.

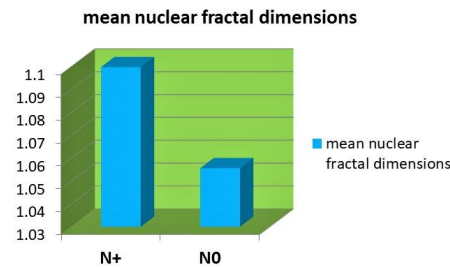


FIGURE 2:

5 | DISCUSSION:

The nucleus of the cell reflects its biological activity. In a normally functioning cell, the nucleus will usually be single in number, round to oval in shape, show even distribution of chromatin, display regular nuclear margin or membrane, one or two inconspicuous nucleoli and normal mitotic figures. As opposed to when the cell undergoes carcinogenesis, the nucleus undergoes numerous alterations of size, shape, number, nuclear membrane or margin, chromatin pattern, nucleoli, and organization of nuclear chromatin [6]. These alterations particularly chromatin clumping is responsible for the irregularity of the nuclear membrane which is reflected as its fractal dimension.

Phulari R et al (2017) applied nuclear fractal dimensions analysis to distinguish between normal oral mucosa, oral epithelial dysplasia and Oral squamous cell carcinoma and observed that NFD can provide valuable information to discriminate between normal mucosa, dysplasia and carcinoma objectively without subjective discrimination [4].

The results obtained in our study were along the same lines as those observed by Goutzanis L et al (2012). They reviewed the applications of nuclear fractal dimensions in the study of oral cancers and proved that FD values increased as the staging of the cancer progressed [5]. Yinti S R et al (2015) supported this finding where nuclear FD increased progressively towards the worst tumour staging as compared to normal buccal mucosa and that the nuclear FD can be considered for quantification of nuclear architectural changes and as a prognostic indicator in OSCC [7].

NUCLEAR FRACTAL DIMENSIONS - AN INDICATOR OF NODAL METASTASIS IN ORAL SQUAMOUS CELL CARCINOMA

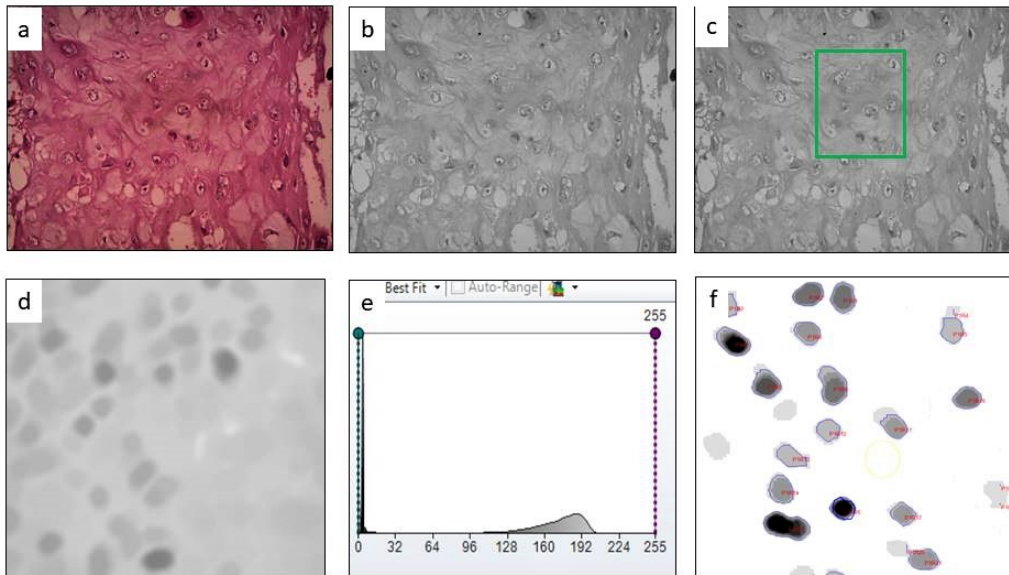


FIGURE 1: Algorithm for analysis of fractal dimensions a. Selecting image and standardizing image analysis b. Applying image red mode to eliminate colours other than white and black. c. Selecting an area of interest d. Creating new image and extracting the background image e. Threshold histogram adjustment f. Extracting the nuclei

The use of digital image system to measure the mean nuclear area, mean nuclear perimeter, nuclear circular rate, ratio of nuclear length to width (aspect ratio), and nuclear area coefficient of variation and correlate it with the differences in nodal status of the tumour stage was done by Karino M et al (2014) [8].

The drawbacks of routine Euclidean geometry were overcome by the advent of Fractal geometry. The presence of processing artefacts such as shrinkage, expansion and distortion of a specimen did not affect the measurement of FD

since the artefacts acted equally in all directions. In comparison, integral dimensions, such as length, perimeter, area etc. are very sensitive to processing artefacts.

Another major advantage of fractal geometric analysis is that the fractal component of dimension was retained whenever a fractal object was projected to a

lower-order dimension [9, 10].

As a generalized observation, tumour growth is almost always associated with increasing irregularity. However it should not be considered as a universal result [11]. An example of this occurrence is the distribution of cells in normal bone marrow which was found to exhibit an increased fractal dimension, as compared to the metastatic lesions of the bone marrow which showed a loss of fractal structure, thus indicating a more uniform filling of the tissue space [11, 12]. Thus, a careful understanding of the disease process along with the Computer aided image analysis is required for an optimum application of this diagnostic aide.

ORCID

Nivedita N Kaorey  <https://orcid.org/0000-0002-2137-9991>

REFERENCES

- [1] Li Q, Wu D, Liu WW, Li H, Liao WG, Zhang XR, Liu ZM, Guo ZM, Liu XK. Survival impact of cervical metastasis in squamous cell carcinoma of hard palate. *Oral surgery, oral medicine, oral pathology and oral radiology*. 2013 Jul 1;116(1):23-7.
- [2] Noguti J. Metastasis from oral cancer: an overview. *Cancer Genomics and Proteomics*. 2012;9(5):329–335.
- [3] Natarajan S, Mahajan S, Boaz K, George T. Morphometric Analysis of Nuclear Features and Volume-Corrected Mitotic Index in the Prognosis of Oral Squamous Cell Carcinoma. *Oral Science International*. 2009;6(2):85–94. Available from: [https://dx.doi.org/10.1016/s1348-8643\(09\)80003-7](https://dx.doi.org/10.1016/s1348-8643(09)80003-7).
- [4] Phulari RS, Rathore R, Talegaon T. Nuclear fractal dimension: A new objective approach for discriminating normal mucosa, dysplasia and carcinoma. *Journal of Oral and Maxillofacial Pathology*. 2016;20(3):400–400. Available from: <https://dx.doi.org/10.4103/0973-029x.190912>.
- [5] Goutzanis L, Papadogeorgakis N, Pavlopoulos PM, Katti K, Petsinis V, Plochoras I, et al. Nuclear fractal dimension as a prognostic factor in oral squamous cell carcinoma. *Oral Oncology*. 2008;44(4):345–353. Available from: <https://dx.doi.org/10.1016/j.oraloncology.2007.04.005>.
- [6] Nandini DB. Cancer Cell Nucleus: An Insight. *J Mol Biomark Diagn*. 2017;2:26–26.
- [7] Yinti SR. Nuclear Fractal Dimensions as a Tool for Prognostication of Oral Squamous Cell Carcinoma. *JOURNAL OF CLINICAL AND DIAGNOSTIC RESEARCH*. 2015;9(11):21–25. Available from: <https://dx.doi.org/10.7860/jcdr/2015/12931.6837>.
- [8] Karino M, Nakatani E, Hideshima K, Nariai Y, Tsunematsu K, Ohira K, et al. Applicability of Preoperative Nuclear Morphometry to Evaluating Risk for Cervical Lymph Node Metastasis in Oral Squamous Cell Carcinoma. *PLoS ONE*. 2014;9(12):e116452–e116452. Available from: <https://dx.doi.org/10.1371/journal.pone.0116452>.
- [9] Fractal geometry: Basic principles and applications in pathology Article. *Analytical and quantitative cytology and histology / the International Academy of Cytology*. American Society of Cytology. 2005;27(5):284–90.
- [10] Mayhew TM. The new stereological methods for interpreting functional morphology from slices of cells and organs. *Experimental Physiology*. 1991;76(5):639–665. Available from: <https://dx.doi.org/10.1113/expphysiol.1991.sp003533>.
- [11] Baish JW, Jain RK. Fractals and cancer. *Cancer research*. 2000;60:3683–3691.
- [12] Moatamed F, Sahimi M, Naeim F. Fractal dimension of the bone marrow in metastatic lesions. Elsevier BV; 1998. Available from: [https://dx.doi.org/10.1016/s0046-8177\(98\)90261-1](https://dx.doi.org/10.1016/s0046-8177(98)90261-1).

How to cite this article: Nivedita N K., Mandakini S M., Jyoti D B., Jayanti G H. Nuclear fractal dimensions - an indicator of nodal metastasis in Oral Squamous Cell Carcinoma. *Innovative Journal of Medical and Health Sciences*. 2020;1036–1039. <https://doi.org/10.15520/ijmhs.v10i06.3014>